



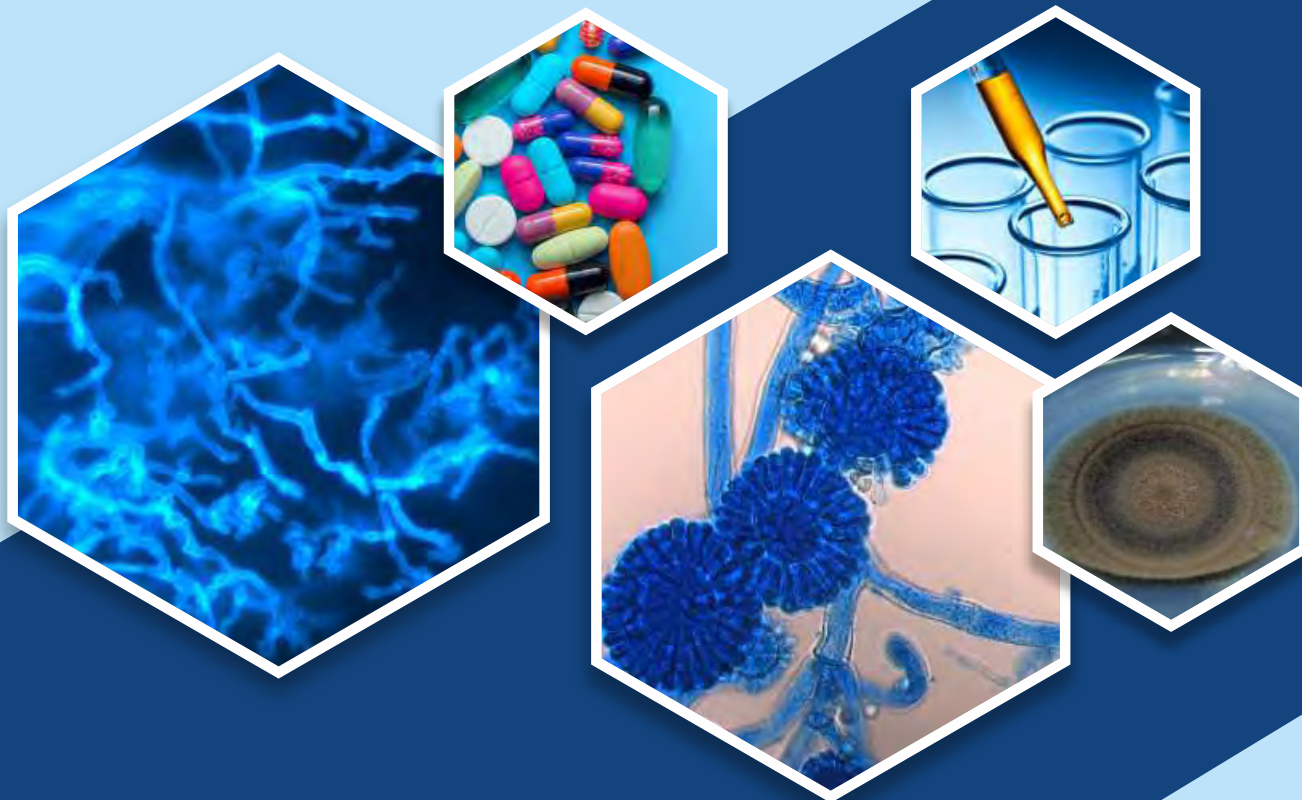
MANIPAL
ACADEMY of HIGHER EDUCATION
(Deemed to be University under Section 3 of the UGC Act, 1956)



McGill



GLOBAL
HEALTH
PROGRAMS



Contagion

The Annual MAC ID News Letter

Issue 2 -August, 2018

Publication by

**Manipal McGill Centre for
Infectious Diseases (MAC ID)**

Prasanna School of Public Health

Manipal Academy of Higher Education, Manipal

Email ID: macid.mu@manipal.edu
Website: <http://macid.manipal.edu/>
Telephone: +91 820 29 33505

Team MAC ID

Team Members: MAHE



Dr Kavitha Saravu

Professor and Unit Chief
Dept. of Medicine, KMC, Manipal
MAC ID Joint Coordinator, Manipal



Dr Shrikala Baliga

Deputy Director
Quality & Compliance, Mangaluru Campus
Professor
Dept. of Microbiology, KMC, Mangaluru



Dr Chiranjay Mukhopadhyay

Associate Dean
KMC Manipal
Professor
Dept. of Microbiology, KMC, Manipal



Dr Kiran Chawla

Professor and Head
Dept. of Microbiology, KMC, Manipal



Dr John Ramapuram

Professor and Head
Dept. of Medicine, KMC, Mangaluru



Dr Sneha Deepak Malliya

Associate Professor
Dept. of Community Medicine, KMC, Manipal



Dr T S Murali

Associate Professor
Dept. of Biotechnology
School of Life Sciences, Manipal

Team Members: McGill University



Dr Madhukar Pai

Director
McGill Global Health Programs, Canada
Associate Director
McGill International TB Center, Canada
Professor of Epidemiology
McGill University, Canada
MAC ID Joint Coordinator, Canada



Dr Nitika Pant Pai

Medical Scientist
The Research Institute of McGill University Health Centre, Canada
Associate Professor of Medicine
McGill University Health Centre, Canada
Researcher, Division of Clinical Epidemiology
McGill University Health Centre, Canada



Dr Michael Libman

Director
J D MacLean Center for Tropical Diseases, Canada
Director, Tropical Diseases Clinic
McGill University Health Centre, Canada
Professor of Medicine
McGill University Health Centre, Canada



Dr Cedric Yansouni

Associate Director
J D MacLean Center for Tropical Diseases, Canada
Assistant Professor
McGill University Health Centre, Canada



Dr Momar Ndao

Director
National Reference Center for Parasitology, Canada
Associate Professor of Medicine
McGill University Health Centre, Canada



Dr Faiz Ahmad Khan

Director, TB Clinical Services, Montreal Chest Institute
McGill University Health Centre, Canada
Respirologist
McGill University Health Centre, Canada
Assistant Professor of Medicine
McGill University Health Centre, Canada

Contents

Section I: Epistola

- | | |
|---|----|
| 1. Editors' notes - Dr Chythra R Rao and Dr Deepak R Madi | 04 |
| 2. Message from Joint Coordinators- Dr Madhukar Pai and Dr Kavitha Saravu | 05 |

Section II: Opus

- | | |
|--|----|
| 1. Events organized by MACID | 08 |
| 2. Seed grants awarded | 14 |
| 3. McGill Summer Course – Participating Faculty Experience | 15 |
| 4. Student Travel Awards | 17 |

Section III: Novus

- | | |
|---|----|
| 1. Articles by McGill faculty | 20 |
| 2. Articles by MAHE faculty | 24 |
| 3. Crossword | 38 |
| 4. Interesting ID related articles published in 2017-18 | 39 |

Section IV: Pictus

- | | |
|---------------|----|
| Photo gallery | 42 |
|---------------|----|

Section V: Laurus

- | | |
|-----------------------------|----|
| MAC ID Faculty achievements | 46 |
|-----------------------------|----|

Section VI: Mustus

- | | |
|--------------------------------|----|
| Upcoming ID conference details | 50 |
|--------------------------------|----|

Section VII: Numus

- | | |
|--------------|----|
| Our Sponsors | 52 |
|--------------|----|

Section 1

Epistola....The letters

Editors' notes



Dr. Chythra R Rao



Dr. Deepak Madi

Dear Readers,

It is indeed a great privilege to be the Newsletter Editors for the second issue of the MAC ID newsletter, Contagion. We acknowledge that it is really a daunting task to keep pace with the benchmark set by our predecessors of the maiden issue.

In this issue we have compiled the steady steps, successes and achievements of the MAC ID collaboration as it steps into childhood. A long way to go before it mellows well with age and experience. Nonetheless, the progress is rest assured with the steady support of the joint coordinators, core committee members and other members of the infectious disease fraternity.

In this issue we have given a snapshot of our activities this year. This issue predominantly focusses on fungal spectrum of the ID profile and an interesting crossword for the intellectuals. A picture gallery showcases various activities and health days observed at Manipal and Mangaluru campuses, with interdisciplinary teams and district stakeholders' involvement.

We thank all the MAC ID members who have contributed to the newsletter with interesting articles, McGill and Manipal faculty for their insights and Chethana for the administrative and documentation support. A special thanks to both the coordinators of MAC ID for their constant support.

Please feel free to provide your feedback and send infectious disease related information with photos and faculty achievements for inclusion in our forthcoming issues. We hope the members have an invigorating read and the Contagion develops effective transmission and permeability.

Message from the Joint Coordinators



Dr Kavitha Saravu

Joint Coordinator
MAC ID, MAHE, Manipal



Dr Madhukar Pai

Joint Coordinator
MAC ID, McGill University, Canada

As MAC ID commemorates second year in August 2018, we are pleased to launch 2nd edition of the newsletter 'Contagion'. In the last two years, we have held academic activities, have supported pilot studies, supported and encouraged young investigators to present their ID work in conferences. We have built on our collaboration with faculty exchanges between Manipal and McGill Universities, and have published jointly.

India continues to hold top spot in many Infectious diseases prevalence including tuberculosis, GI infections, and pneumonia to name a few. Increasing antimicrobial resistance, drug resistance in TB and malaria put the fight against microbes at crossroads. Emerging infectious diseases underscore the importance of emergency preparedness to manage and counter the outbreak. These threats and challenges provide us opportunities to step in and contribute to public health. It has never been more relevant than today to have essential diagnostics in place to ensure that essential medicines are put to use appropriately.

While we look back at the year that we have traversed with satisfaction, we look forward to the road ahead with ambition and aspirations under the able guidance of our University leadership. We congratulate Dr Shrikala Baliga and her team in KMC Mangaluru for hosting MAC ID international conference in Mangaluru in 2018. We compliment and congratulate Dr Chythra Rao, and Dr Deepak Madi for editing this issue of 'Contagion', and for their creative craftsmanship.

Section 2

Opus....
The work so far....

1. Events Organized by MAC ID

A. Manipal Infectious Diseases Conference & MAC ID Annual Day – 22nd & 23rd August, 2017



Inauguration of Manipal Infectious Diseases Conference



Release of MAC ID Newsletter "CONTAGION" ISSUE -1

From Left to Right: Dr Manjunatha Hande, (Professor and HOD of Medicine, KMC Manipal); Dr Madhukar Pai, (Director McGill Global Health Programs, Canada); Dr Vinod Bhat (Vice Chancellor, MAHE, Manipal); Dr Poornima Baliga (Pro-vice Chancellor, MAHE, Manipal), Dr Pragna Rao (Dean, KMC, Manipal), Dr Kavitha Saravu, (Professor of Medicine, KMC Manipal)

The two-day conference on Infectious Diseases organised by Manipal McGill Centre for Infectious Diseases (MAC ID), along with Department of Medicine, Kasturba Medical College Manipal, McGill Global Health Programmes and T.M.A. Pai Endowment Chair in Translational Epidemiology and Implementation research on 22nd and 23rd August, 2017, discussed a whole gamut of issues related to infectious diseases.

The conference attended by nearly 200 faculty members, postgraduate students and researchers, was inaugurated by H. Vinod Bhat, Vice-Chancellor, Manipal Academy of Higher Education, Manipal.

Chandrasekar, Chief of Infectious Diseases from Wayne State University, Detroit, delivered the keynote address on recent advances in the diagnostics of fungal infections for earlier diagnosis to reduce mortality.

Madhukar Pai from McGill University, Montreal, spoke about the need for an Essential Diagnostics List. He emphasized the need of such a list in improving patient care, detecting outbreaks, increasing affordability of tests, reducing out-of-pocket expenses for tests, reducing antibiotic abuse and guiding research and development of new diagnostic tools.

Dr Momar Ndao from McGill University, Montreal, the Director of National Reference Laboratory for parasitic diseases, Canada spoke on diagnosis of parasitic diseases. In a key note address, Dr Padmini Srikantiah, from Center for Disease Control, USA's Global Diseases Detection program, who investigated the Muzzafarpur "Litchi" induced hypoglycemic encephalopathy outbreak in India spoke on outbreak investigation emphasizing the need for a systematic approach in investigating outbreaks to prevent such events from recurring.

Infectious Diseases experts led by Dr Chakrapani M, Associate Dean, KMC Mangaluru shed light on the problem of antimicrobial resistance (AMR) and the role of diagnostic stewardship and strategies of antimicrobial stewardship to overcome this crisis. Dr George M Varghese outlined the challenges in management of resistant Gram negative infections prevailing in India and cautioned about the limited pipeline of drugs against Gram negative infections.

Other speakers included Dr Rajeev Soman, ID consultant from P D Hinduja hospital and Dr Binila Chacko, Professor from Christian Medical college, Vellore. Half a day was dedicated to lectures on non-AIDS issues in the management of HIV, Understanding HIV resistance upon treatment and nuances of their management and new strategies in HIV care with paradigm shifting towards long term suppressive therapy of HIV with two highly efficacious drugs.

B. World Pneumonia Day – 15th November, 2017



Inauguration of Poster Competition by
Medical Superintendent of Kasturba Hospital,
Manipal - Dr (col) M Dayananda



Skit team with MAC ID Joint Coordinator Dr Kavitha Saravu;
HOD of Medicine Dr Manjunath Hande and Skit organizer
Ms Latha, Assisatnt Professor, MCON & Dr Mamatha
Shivananda Pai, Professor and
HOD dept of Child health nursing, MCON

- (i) On the eve of World Pneumonia Day 2017 an awareness program was jointly organized by the Manipal McGill Center for Infectious Diseases, Kasturba Hospital, Manipal, and Manipal College of Nursing, Manipal. Poster competition was organized for Students and faculty of Manipal University on the theme "Stop Pneumonia: Invest in Child Health" and were displayed in the outpatient department of Kasturba Hospital. Furthermore, students of Manipal College of Nursing presented Educational skit in the hospital for patient awareness on "Pneumonia", which was well appreciated by patients.
- (ii) A half day CME was held on 15th November, 2017 which was attended by 100 faculty members, students and research scholars. Dr Helmut Brand, Director of Prasanna School of Public Health was the Chief Guest and Dr (Col) M Dayananda, Medical Superintendent & COO of Kasturba Hospital, Manipal was the Guest of Honour. CME speakers, Dr. Shantharam Baliga (Professor of Pediatrics, KMC Manipal), Dr Swati Ragagopal (Consultant- Infectious Disease and Travel Medicine, Aster CMI Hospital, Bangalore), highlighted on Pneumonia in Children: The Road Ahead and Community Acquired Pneumonia in Adults: The Burden, Evolving Trend & Case Management followed by a panel discussion on Prevention of Pneumonia: Are We Doing Enough? Quiz competition for post graduates was organized by Dr Suneel C Mundkur on "Respiratory Infections".
- (iii) Health Issue Article in Arogyavani (local newspaper) on "Pneumonia" by Dr Sneha Deepak Mallya (Dept of Community Medicine, KMC Manipal), Dr Kavitha Saravu (Dept of Medicine, KMC Manipal)
- (iv) Interview and phone in program in the regional television on "Pneumonia" by Dr Kavitha Saravu on 18/11/2017 and radio talk on Childhood pneumonia by Dr Suneel C Mundkur, Professor of Paediatrics on 15/11/2017.

C. Symposium on Optimizing Antibiotic use in Hospitals - 18th November, 2017



Organized by Department of Medicine and Department of Microbiology, KMC Mangaluru

A full day Symposium on “Optimizing Antibiotic use in Hospitals” was organized by Departments of Microbiology and Medicine, Kasturba Medical College, Mangaluru in collaboration with MAC ID, Manipal Academy of Higher Education on 18th November 2017 at KMC, Mangaluru.

The sessions began with Principles of antimicrobial therapy by Dr Chakrapani M, Associate Dean, Professor of Medicine, KMC Mangaluru. He stressed on the fact that the clinical progress and patient should be given priority during treatment. In the second session, Dr Suchitra Shenoy M, Associate Professor, Microbiology, KMC Mangaluru spoke about Interpretation of antibiogram. The participants were introduced to the mechanisms of antibiotic resistance in bacteria and how they can be detected in the laboratory. She gave a brief on how to choose the appropriate antibiotic in ideal situation. Dr Sheetal Ullal, Associate Professor, Pharmacology, KMC Mangaluru briefed the participants about the PK- PD, MIC and dose optimization of antibiotics. Dr Basavaprabhu A, Associate Professor, Medicine, KMC Mangaluru, discussed about dosage adjustments in special populations. He stressed on the points in renal or hepatic impairment and drug interactions. The session was concluded with a Panel Discussion on nine different infectious disease cases.

D. World TB Day -19th - 24th March, 2018



Inauguration of TB Symposium
From left to right: Dr. Muralidhar Kulkarni, Dr Aswini Kumar Mohapatra, Dr Ashwini Kumar, Dr Somashekar, Dr. Rahul Magazine (lighting the lamp)



From left to right: Dr Ashwini Kumar, Dr Kavitha Saravu, Dr Chidanand Sanju, Dr. Pragna Rao (Dean KMC Manipal) Dr Suma Nair, Dr Kiran Chawla

Department of Community Medicine, Pulmonary Medicine, Manipal McGill Center for Infectious Diseases (MAC ID) and District Health Society (TB Division) Udupi District organized six days (19.03.2018 to 24.03.2018, from 2 to 5 pm) sensitization programme for Faculty Post Graduates, Interns and Nursing Staff of ten TB managing departments on "Recent changes in Technical and operational guidelines of RNTCP" at KMC Manipal. 128 faculty members, 111 Post Graduates and interns and 54 staff nurses attended the programme. Dr Ashwini Kumar Nodal officer RNTCP gave brief note on evolution of TOG 2016 and need for following standard uniform mode of diagnostic methods and treatment of tuberculosis.

Invited speakers were: Dr. Somashekar N, Sr. TB Specialist, NTI (National Tuberculosis Institute), Bangalore, Dr. Arjun S Nayak Manel, In charge of DR-TB centre, GWH Mangaluru, Asst. Prof. Dept. of General Medicine, KMC, Mangaluru, Dr. Deepu Changappa, National TOT, Asst. Prof. Dept. of Respiratory Medicine, YMC, Mangaluru.

And internal speakers were: Dr Ashwini Kumar, Nodal officer RNTCP, Additional Professor, Dept. of Community Medicine KMC Manipal, Dr. Rahul Magazine, Prof. & HOD, Dept. of Pulmonary Medicine, KMC, Manipal, Dr. Kiran Chawla, Prof. & HOD, Dept. of Microbiology, KMC, Manipal, Dr. Kavitha Saravu, Prof and Unit Head, Dept. of General Medicine, KMC, Manipal and Joint coordinator of Manipal McGill Center for Infectious Diseases, MAHE, Manipal, Dr. Muralidhar Varma, Associate Professor, Dept. of General Medicine, KMC, Manipal, Dr Vishnu Prasad, Associate Professor of Microbiology, KMC Manipal. Dr. Amitesh, Asst. Prof. Dept. of Respiratory Medicine, KMC, Manipal, Dr. Vyshak U S, Asst. Prof. Dept. of Respiratory Medicine, KMC, Manipal, Dr. Sadhana N Holla, Dept. of Pharmacology, KMC, Manipal

The topics discussed were: TB case finding, laboratory diagnosis of TB, treatment algorithms, MDRTB algorithms, adverse drug reactions in tuberculosis, and how to protect health care workers from tuberculosis.

Valedictory function was held on 24.03.2018 commemorating world TB day. The dignitaries included, Dr Pragna Rao, Dean KMC, Manipal, District TB officer Dr Chidanand Sanju, HODs of Pulmonary Medicine, Community Medicine, Microbiology and Dr Kavitha Saravu.

E. World Malaria Day – 25th April 2018



From left to right: Dr Narayana Sabahit, (Registrar, MAHE, Manipal), Dr Suma Nair, (HOD, Dept. of Community Medicine, KMC, Manipal), Dr Pragna Rao, (Dean KMC, Manipal), Dr Manjunath Hande, (HOD, Dept. of Medicine, KMC, Manipal), Dr Kavitha Saravu, (Prof. Dept. of Medicine, KMC, Manipal)



From left to right: Dr Ashwini Kumar, (Additional Professor, Dept of Community Medicine, KMC Manipal) Dr Shrikiran A Hebbar, (Professor and Head, Dept of Pediatrics, KMC, Manipal) Dr Shashikiran U, (Professor, Department of Medicine, Dr TMA Pai Hospital Udupi) Dr Animesh Jain, (Professor and Head, Dept of Community Medicine, KMC Mangalore) and Dr. Premanand (District Malaria Officer, Udupi)

On the eve of World Malaria Day 2018, an awareness program was jointly organized by the Manipal McGill Center for Infectious Diseases, Department of Community Medicine and Department of Medicine at KMC Manipal. Street play competition was organized for Students and faculty of Manipal Academy of Higher Education on the theme “End Malaria for Good”. Five teams participated in the street play competition, MBBS students from KMC Manipal, Manipal College of Dental Sciences, and participants from Department of Medicine won first, second and third place respectively.

A half day continuing medical education (CME) program, was held on 25th April, 2018 at KMC Manipal which was attended by 120 faculty members, students and research scholars.

The CME was inaugurated with the brief address by the Chief Guest, Dr Narayana Sabahit, Registrar, Manipal Academy of Higher Education, Manipal. Dr Pragna Rao, Dean of Kasturba Medical College, Manipal was the Guest of Honor. Dr Manjunatha Hande, Professor and Head, Department of Medicine welcomed the gathering. Prizes were distributed to the winners of Street play competition.

The first session began with Diagnosis of Malaria by Dr Chethan Manohar, Professor of Pathology, KMC Manipal. She stressed on the basics of diagnosis of malaria such as microscopy and rapid diagnostic tests. In the second session, Dr Kavitha Saravu, Professor and Unit Chief of Medicine, KMC Manipal and Joint coordinator MAC ID, MAHE, Manipal spoke about Perils and Pitfalls of Management of Malaria. She called for high index of suspicion for malaria in endemic areas, timely accurate diagnosis by quality assured tests and responsible prescribing by the providers.

A Panel Discussion was held on Opportunities & Challenges to Malaria Control in Coastal regions. The panel discussion was led by Dr Ashwini Kumar, Additional Professor, Department of Community Medicine, KMC Manipal and the panelists included Dr Premanand, District Malaria officer, Udupi, Dr Animesh Jain Professor and Head, Department of Community Medicine, KMC, Mangaluru, Dr Shashikiran Umakanth, Professor, Department of Medicine, Dr TMA Pai Hospital, Udupi and Dr Shrikiran A Hebbar Professor and Head, Department of Pediatrics, KMC Manipal. Panelists discussed about the challenges of vector control, G6PD deficiency, and management. They deliberated upon the measures Sri Lanka followed to be successful at eliminating malaria and the methods currently introduced in Mangaluru City Corporation.

F. Invited Lectures



Infections in Immunocompromised host: Talk by Dr Cedric Yansouni

Dr Cedric Yansouni is Associate Director of the J.D. MacLean Centre for Tropical Diseases, Assistant Professor of Infectious Diseases and Medical Microbiology at the McGill University Health Centre in Montreal, Canada

Dr Cedric provided a case-based approach to infections in immunocompromised hosts. He discussed the manifestations and treatment of selected life-threatening opportunistic parasitic infections, especially strongyloidosis.






Implementation strategy to improve the Impact of rapid blood culture diagnostics: Talk by Dr Ritu Banarjee

Dr Ritu Banarjee is Associate Professor, Pediatric Infectious Diseases, and Director, Pediatric Antimicrobial Stewardship Program, Vanderbilt University, Nashville, TN, USA

Many strategies and technologies are available to improve blood culture (BC)–based diagnostics. The ideal approach to BCs varies between healthcare institutions. Institutions need to examine clinical needs and practices in order to optimize BC-based diagnostics for their site. The optimal diagnostic test or implementation strategy needs to be individualized for each institution, based on unique microbiology, local prevalence of resistance mechanisms, antimicrobial prescribing patterns, and antimicrobial stewardship activities. Dr Ritu Banarjee's talk reviewed the evidence that rapid testing together with antimicrobial stewardship interventions provide more favorable outcomes than rapid testing alone, and will provide examples of implementation strategies for BC diagnostics that have been effective in some US institutions.

2. Seed Grants Awarded

Awardees Name & Department		Title of the project
Dr G Sreejith Dept of Microbiology MMMC, Manipal, MAHE		Developing and evaluating the efficacy of a paper based rapid diagnostic test for dengue using zinc oxide quantum dots
Dr Sindhura Lakshmi Dept of Pathology KMC, Manipal, MAHE		Role of intracellular cytokine flow cytometry in assessing tuberculosis specific cytokines to differentiate between active and latent tuberculosis
Dr Naresh Kumar Mani Dep of Biotechnology MIT, Manipal, MAHE		PADS: "Engineering Miniaturized Paper-based Analytical Devices for Point-of-Care (POC) diagnosis & antibiotic susceptibility of Candidiasis"
Dr Sevitha Bhat Dept of Microbiology KMC, Mangaluru, MAHE		Utility of direct detection of mec A gene in clinical specimen for detection of Methicillin Resistant Staphylococcus aureus
Dr Navya Vyas Dept of Public Health PSPH, Manipal, MAHE		Multicentric observational study on protective effect of metformin against tuberculosis infections in diabetic patients in South-Indian tertiary healthcare facilities
Dr Ritu Raval Dep of Biotechnology MIT, Manipal, MAHE		Exploring the immunomodulatory properties of chitosan derivatives

3. McGill Summer Course - Participating Faculty Experience



Dr. Chythra R Rao.

Associate Professor,
Department of Community Medicine
Kasturba Medical College, Manipal.

The trip to McGill at Montreal was an overall delightful experience. I owe it to the selection committee and the Joint Coordinators, Dr Kavitha Saravu and Dr Madhukar Pai from MACID for the wonderful opportunity to visit Montreal and have a glimpse of the remarkable work being done there. Ms. Stephanie and Kristin very efficiently coordinated the registration, travel and accommodation arrangements and continued to guide us through the summer course for all logistic issues.

On my arrival at Montreal, I decided to explore the summer course venue from our accommodation. To my surprise every alternate building in the vicinity was a McGill building. Then it dawned on me that I was in McGill land. It was truly an Alice in wonderland experience.

The first course I had opted was on Qualitative methods for research. The course co-ordinators and faculty, Amrita Daftary, Nora Engel, Joanne Mantell, Mike Callaghan, Andy McDowell and Jennifer Furin were very amiable and approachable. The five-day course was very interactive and informative; beginning the day with interactive lectures and working out details for a probable collaborative proposal in the afternoon sessions. Participants from across the globe and from diverse backgrounds added flavor to the discussions. The energy, experience and enthusiasm of the faculty and the nature of the qualitative work that they had carried out in India was indeed an eye opener.

During the second week, the course on Clinical Tropical Medicine largely focused on neglected tropical diseases. The core course faculty, Michael Libman, Cedric Yansouni, Sapha Barkati, left no stone unturned in bringing together seasoned ID specialists, interesting case vignettes and diagnostic dilemmas for the benefit of the course participants. It was very surprising to note the wide variety of tropical diseases that were being diagnosed and managed at the Tropical Medicine Centre and Travel Clinic at the McGill University Health Centre.

In addition, Sapha Barkati, Cedric Yansouni and Momar Ndao were kind enough to take my colleague Dr Shashidhar and I, around the McGill University Health Centre. The efficiency, protocols and functioning of the travel clinic, laboratories and out-patient clinics at the MUHC was noteworthy.

Apart from academics, the evening walks around the city, visit to old port area, the climb to Mount Royale was amazing. The weekend trip to Quebec city and Botanical gardens was awesome. The icing on the cake was the interaction with Dr Madhukar Pai and Team Pai girls. The all-girl team was remarkable, they took us for dinner, guided us through the city and literally provided 'Z' security for us. Dr Madhu was such a wonderful host. In addition to all the amenities at the hotel, facilities at the venue, good food, wine and cheese reception, he also treated us with great Indian cuisine. The typical south Indian palate was soothed with Masala Dosa, idli, vada and sambhar at the Thanjai restaurant. Great memories to carry back home.

The opportunity to visit McGill was truly a remarkable experience with fond memories to relish for times to come and I truly thank the MAC ID collaboration for providing this platform.



Dr Shashidhar V

Associate Professor,
Department of Microbiology,
Kasturba Medical College, Manipal

I wish to thank Manipal McGill Center for Infectious Diseases for the opportunity provided to attend the two weeks McGill Summer Institute in Infectious Diseases and Global Health in Montreal, Canada. The registration process was very easy and quick. The summer Institute website is very informative and helps one to choose the course of interest of the many options available. Thanks to Ms. Stephanie and Ms. Kristin from Global Health Programs for all the support provided for registration, travel, and accommodation. Our accommodation was in Carrefour Sherbrooke close to the course venue, Centre Mont-Royal. The weather was excellent throughout with very light showers in between.

The Global Health Diagnostics course in the first week was unique both in terms of content and delivery. I found Tech Pitch to be very interesting. This Institute attracts delegates of multiple nationalities from diverse backgrounds including physicians, clinical microbiologists, public health professionals, government sector, laboratorians, product developers, and students. One gets to hear from and interact with this diverse array of professionals. I have to congratulate Dr. Madhukar Pai, Dr. Nitika P Pai and Dr. Cedric Yansouni for this wonderfully structured course. I was initially a bit hesitant enrolling for the Genomic Epidemiology course but soon felt it very interesting and useful with plenty of practical sessions and journal clubs. Thanks to Dr. Marcel Behr and Dr. Robyn Lee, the course directors. Also, got to see a variety of parasites in the Tropical Medicine Lab course in the weekend. Nice, extensive collection of slides indeed. Thanks to Dr. Chythra Rao for coordinating the visit to MUHC, Dr. Sapha Barkati and Dr. Momar Ndao for taking us through the Tropical Disease clinic and their extensive diagnostic and research lab facilities. The huge statue of a stethoscope symbolizing the relationship of trust between physician and patient in front of the MUHC Adult hospital was very appealing.

Apart from the extensive sessions, there is plenty of time to explore the beautiful city of Montreal as the days are pretty long. Old Montreal is a visual treat. Mount Royal, Jardin Botanique and visit to Quebec City are a must. Pure vegetarian hotel options are available at McGill campus for the strict veggies. Thanks to Dr. Pai for the South Indian treat of masala dosa and Idlis at Thanjai Restaurant famous for six feet masala dosas. I wish to say that two weeks at the Institute are worth spending for anyone working in the field of Infectious Diseases and would recommend others to apply for the summer course in the coming years. Finally, thanks to Dr. Kavitha Saravu and Dr. Madhukar Pai the Joint co-ordinators of MAC ID for bringing together this opportunity for MAHE faculty.

A truly, memorable experience to cherish.

4. Student Travel Awards

Sahil Sahay - 3rd Year MBBS, Department of Immunohematology and blood transfusion, KMC Manipal

Title: Evaluation of Platelets Transfusion Practice In Managing Dengue Patients

Poster Presentation at ILLUMINATI 2017

Organized by Armed forces Medical College at Pune on 09th - 10th September, 2017

Basharath Husseni Khan - 3rd Year MBBS, Department of Microbiology, KMC Manipal

Title: "YOUNG IMMATURE COCONUT: Can it open a new era to treatment of enteric pathogens"

Poster Presentation at 14th Asian Conference on Diarrhoeal Diseases and Nutrition (ASCODD) held at Kochi, India from 30th October - 1st November, 2017

Sujith Pavan - PhD, Department of Microbiology, KMC Manipal

Title: Vibrio to aeromonas: A changing trend in Diarrhoeal etiology in coastal Karnataka

Poster Presentation at 14th Asian Conference on Diarrhoeal Diseases and Nutrition (ASCODD) held at Kochi, India from 30th October - 1st November, 2017

Sai Mounika Cherukuri - Post Graduate, Department of Medicine, KMC Manipal

Title: Predictors of Mortality In Patients with Candidemia

Poster Presentation at 73rd Annual Conference of the Association of Physicians of India APICON 2018 held from 22nd - 25th February 2018 at Bengaluru, Karnataka, India

Section 3

Novus....
Whats New in ID

1. Articles by McGill Faculty

[A]. Quality health care begins with diagnosis

Madhukar Pai & Kamini Walia

Dr Madhukar Pai is the Director of Global Health at McGill University, Montreal. Dr Kamini Walia is a Senior Scientist with the Indian Council of Medical Research, New Delhi.
Both served on the WHO expert group that developed the EDL.

<https://www.thehindu.com/sci-tech/health/it-begins-with-diagnosis/article24002788.ece>, May 27 2018

How often have you popped in antibiotics without quite knowing what infection you had? Whether it is fever, diarrhea, or cough, medicines are heavily over-prescribed, while diagnostic tests are rarely used. And this problem is not limited to infections. Nearly one in two Indians with diabetes are unaware that they have diabetes. Cancers are usually detected when they are advanced, resulting in poor survival rates.

In India, patient studies show that primary care providers in both urban and rural areas make a correct diagnosis in less than a quarter of patients who present with typical symptoms of angina, TB, asthma, and pneumonia. The studies also show excessive use of medicines, and very little testing. Not surprisingly, India is one of the world's biggest consumer of antibiotics, and antibiotic resistance is a looming threat.

Laboratory tests are also important for public health. Every year, dozens of outbreaks occur without any clarity on what is causing them. A fever outbreak could be due to dengue, malaria, influenza, Chikungunya, or scrub typhus. Laboratory testing is the only way to know.

Ideally, treatment will follow diagnosis, and treatment will be tailored to the exact cause of illness. Sadly, as the above examples illustrate, this rarely happens. Lack of access to good, affordable testing is one reason why healthcare providers bypass the process of diagnosis.

WHO released the EDL to address this gap. Of the 113 tests included, 58 are basic tests (e.g. hemoglobin, blood sugar, blood cell counts, pregnancy test) for detection and monitoring of a range of conditions. The remaining 55 tests can diagnose common infections, including HIV, TB, malaria, hepatitis B and C, human papillomavirus and syphilis.

While some of these tests are essential for delivering primary health care, others are meant for higher-level facilities with clinical laboratories (e.g. district hospitals).

Why do we need an EDL? Universal Health Coverage (UHC) is the core of WHO's mission, and access to quality, affordable primary health care is fundamental to achieve UHC. In India, the Ayushman Bharat scheme of the Indian government will be centered around Health and Wellness Centres that aim to deliver comprehensive primary care.

But quality primary health care cannot be delivered with only medicines. Patients need access to early and accurate diagnosis. How can health workers and doctors treat diseases, if they can't diagnose them? How can essential medicines be delivered, without essential diagnostics?

As medicines become expensive, and antimicrobial resistance emerges, we simply cannot afford to consume medicines like candies. Investing in diagnostics can not only improve effectiveness of treatment, it can also reduce costs and unnecessary drug use.

The scale-up of malaria rapid tests led to a substantial decline in the use of anti-malarial drugs. On the other hand, not having good, easy to use tests for typhoid and TB have resulted in the emergence of extremely drug-resistant bacteria.

While India has a National List of Essential Medicines since 2003, there is no equivalent list of essential diagnostics. Our policy makers forgot to think about tests.

This will soon change. Thanks to the initiative of the Indian Council of Medical Research and WHO India, India has started developing a National List of Essential Diagnostics, to complement the NEML.

Both lists, taken together, will form the basis of providing essential primary care services across the country, and greatly improve quality of care. Both lists can be used to impose price controls, streamline supply chain, and ensure better access.

But lists alone will not change the reality. States will have to invest in strengthening public laboratories, contract private laboratories as required, and make sure quality-assured testing services are freely available at all facilities. This is underway via the Free Diagnostics Service Initiative by the government, and can be further expanded and strengthened with the National EDL.

In a Lancet study this week, India was ranked 145th among 195 countries in terms of health care access and quality. It is time we not only increased coverage of health care, but also improved quality of care. Access to essential tests is the first key step in improving quality of care.

[B]. Health care is an essential human right – and so is a proper diagnosis
May 17, 2018

Madhukar Pai

The Conversation

<https://theconversation.com/health-care-is-an-essential-human-right-and-so-is-a-proper-diagnosis-96397>

Health is a human right. And yet, the sad reality is that, 40 years after the Alma Ata declaration pledging “Health For All,” half the world is still without access to essential health-care services.

To address the global health-care crisis, all countries must commit to the Sustainable Development Goals by 2030, which include Universal Health Coverage. This involves financial risk protection, access to quality essential health-care services and access to safe, effective, quality and affordable essential medicines and vaccines for all.

In a path-breaking development, 40 years after publishing the first Essential Medicines List, the World Health Organization (WHO) this week published the first Essential Diagnostics List.

This new list will greatly enhance the impact of the Essential Medicines List (EML). After all, essential medicines require essential diagnostics.

While everyone accepts the importance of essential medicines and vaccines, there is little acknowledgement of the central importance of diagnosis - the first, critical step in the management of all diseases.

Diagnostics influence about 70 per cent of health-care decisions, and yet only three to five per cent of health-care spending goes into tests.

Addressing the diagnostic gap

Imagine treating tuberculosis (TB) without a diagnosis, or managing diabetes without access to lab testing. It is stunning that in 2018, nearly 40 per cent of the estimated TB cases are either not diagnosed or not reported. An estimated 46 per cent of adults with Type 2 diabetes worldwide are undiagnosed. Millions of episodes of acute fevers are managed by health-care providers without any diagnosis.

How can we deliver quality primary health care, if we can't even diagnose common and priority conditions? And how can we detect and control outbreaks, if we don't know what we are dealing with?

This week, WHO took a huge step in addressing this diagnostic gap, by publishing its first Essential Diagnostics List (EDL), a list of the tests needed to diagnose the most common conditions as well as a number of global priority diseases.

Essential diagnostics are defined as diagnostics that satisfy the priority health-care needs of the population and are selected with due regard to disease prevalence and public health relevance, evidence of efficacy and accuracy and comparative cost effectiveness.

What does the first EDL include?

The first EDL, compiled by a WHO expert advisory group on in-vitro diagnostics, contains 113 tests.

Of these, 58 are basic tests (e.g. hemoglobin, blood glucose, complete blood count, urine dipstick) intended for detection and diagnosis of a wide range of common communicable and non-communicable conditions.

These basic lab tests form the basis for an essential package of tests at the level of primary care and higher. The remaining 55 tests are designed for the detection, diagnosis and monitoring of “priority” infections — namely HIV, TB, malaria, hepatitis B and C, human papillomavirus (HPV) and syphilis.

All tests included in the EDL are backed by existing WHO evidence-based guidelines. The list is presented in two tiers: Primary health care and health care facilities with clinical laboratories.

WHO will update the EDL on a regular basis, just as the EML is kept updated. WHO has plans to expand the list significantly over the next few years, and to include tests for antimicrobial resistance, emerging infections, neglected tropical diseases and additional noncommunicable diseases.

Implementing for impact

There are at least 10 potential benefits to an EDL: These include improving patient care, helping detect outbreaks, increasing affordability of tests, reducing out-of-pocket expenses for tests, reducing antibiotic abuse, improving regulation and quality of diagnostic tests, strengthening accreditation and quality of laboratories, improving supply chain and guiding the R&D of new diagnostic tools.

While the WHO EDL is a welcome development, the list, by itself, will not have an impact. To see a meaningful impact, countries will need to adopt and adapt the WHO list, and develop their own national lists.

Once national EDLs are in place, then mechanisms can be put in place to improve the availability, affordability and quality of included tests.

India, for example, has already begun the process to develop a national EDL. Hopefully, other countries will follow suit and find ways to realize the potential of an EDL in their settings.

Time to invest in laboratories

In addition to developing national EDLs, countries must invest in strengthening their laboratory networks. Currently, laboratory capacity is weak in many low-income countries, because of four key barriers: Insufficient human resources, inadequate education and training, inadequate infrastructure and insufficient quality, standards and accreditation.

Why have countries under-invested in laboratories? For too long, the global health community systematically promoted empirical or syndromic treatment for many conditions in low-income settings, because building a reasonable laboratory infrastructure was considered too difficult and expensive.

This explains the emphasis on “essential medicines” for more than 40 years, and the lack of an essential diagnostics list until now.

And then came the push in the 1990s to develop, implement and create a market around simple rapid tests (driven by malaria and HIV, mostly), as laboratory infrastructure was still scarce. However, the excessive focus on rapid, point-of-care tests (that still continues) further pushed back serious investments in laboratory strengthening.

Improvement of laboratories and strengthening health systems is still considered too expensive and difficult by most governments and donors. This explains why we struggle to manage conditions for which no good rapid tests exist. This also explains why health systems with weak laboratory infrastructure cannot detect outbreaks early, nor offer comprehensive diagnostic services that cover a wider range of conditions, including antimicrobial resistance and non-communicable diseases.

It is time to reject the mindset that rapid tests and syndromic treatments are “enough for poor countries,” and work towards ensuring that all countries have a functional, tiered, quality-assured laboratory infrastructure.

Universal health coverage requires essential diagnostics, and diagnostics cannot be delivered without investments in health systems.



Laboratory infrastructure is weak in many low and middle income countries. (Madhukar Pai), Author provided



A nurse conducts tests in a primary care clinic in South Africa. (Madhukar Pai), Author provided

[C]. McGill Summer course - 11th -22nd June, 2018

Cédric Yansouni^a, Sapha Barkati^b

^aAssistant Professor, Division of Infectious Diseases, Department of Medical Microbiology
Associate Director, J.D. MacLean Centre for Tropical Diseases
McGill University Health Centre

^bAssistant Professor, Division of Infectious Diseases, Department of Medical Microbiology
McGill University Health Centre

Once again this year, MAC-ID members from KMC contributed to the 2018 edition of the McGill Summer Institute for Infectious Diseases and Global Health, June 11-22. This fourth edition of the Summer Institute comprised 6 courses in total, and attracted 687 participants (122 faculty members) from 53 countries.

Dr. Chythra. R. Rao, Associate Professor in the Department of Community Medicine, and Dr. Shashidhar Vishwanath, Associate Professor in the Department of Microbiology, travelled from KMC to Montreal to participate in three courses of this year's Institute, and liaise with McGill MAC-ID faculty.

The courses and forums this year included Global Health Diagnostics (co-directors Cédric Yansouni, Nitika Pant Pai, and Madhukar Pai), which is now featured in a Nature microbiology blog: <https://naturemicrobiologycommunity.nature.com/users/121447-shona-jane-lee>.

Drs. Amrita Daftary and Nora Engel co-directed the popular Qualitative Methods in Global Infectious Diseases Research course, focused on the principles and rigorous application of qualitative methods in formative, operational, evaluation and policy research in tuberculosis, HIV/AIDS, and malaria.

Both Drs. Rao and Vishwanath attended the J. D. MacLean Centre for Tropical Diseases' long running Clinical Tropical Medicine course (co-directed by Michael Libman and Cedric Yansouni), focused on linking laboratory diagnostics and research to the clinical treatment of patients for key infectious syndromes in the tropics.

MAC-ID continues to sow collaborations and strengthen relationships that are bearing fruit in the forms of trainings, collaborative research, and student exchanges which are planned for the coming year.

2. Articles by MAHE Faculty (Review and Case Reports)

[A]. Clostridium difficile - Epidemiology and Diagnosis

Deepika VB^a, Murali TS^a

^aDepartment of Biotechnology, School of Life Sciences, MAHE, Manipal

Clostridium difficile, a Gram positive anaerobic bacillus, is a major nosocomial pathogen infecting humans. The organism was first identified by Hall and O'Toole in 1935[1] as a part of a study that assessed the changes in microbial profile in the faeces of infants. For several years, the organism was considered to be a part of normal faecal microbiota and various reports in the mid-1980's on the virulence properties of the toxins produced by the bacterium suggested *C. difficile* to be the pathogen responsible for Pseudomembranous colitis [2]. *C. difficile* is now rightly regarded as a global public health concern especially in healthcare settings. Symptomatic, asymptomatic and undiagnosed patients, health care workers act as major reservoirs for transmission of *C. difficile* [3]. Genetically these microbes are highly diverse species that includes both toxin-producing pathogenic forms and non-toxin producing non-pathogenic forms [4]. The onset of the infection begins with the germination of the bacterium spores and production of toxins in the gut lumen. Disruption of colonic epithelial cells and stimulation of pro-inflammatory cytokines and chemokines is observed with the release of exotoxins TcdA-toxin A and TcdB-toxin B leading to severe inflammatory response initiating acute inflammation of the large intestine[5,6]. The symptoms range from mild diarrhea to dilated bowel (toxic megacolon), perforation of colon, sepsis and in more than 17% of cases, even death. The infection severity, risk of recurrence and mortality is highly influenced by characteristics of strain and host's immune response with older people being more vulnerable to infection [6,7].

Detection protocols to understand the epidemiology of *C. difficile* is a major shortcoming due to the lack of globally accepted sequence typing methodologies. Most commonly used techniques include MLST (multi-locus sequence typing), PFGE (pulsed-field gel electrophoresis), REA (restriction endonuclease analysis), ribotyping and MLVA (multi-locus variable-number tandem-repeat analysis)[8]. In fact, combination of these techniques has been found to be more effective in differentiating the strains. REA and MLVA is considered to provide better discrimination in the strains compared to ribotyping or MLST[8,9].

Much importance is being currently focused on *C. difficile* detection. As the species is diverse (pathogenic and non-pathogenic forms) and horizontal transfer of toxin encoding loci is a common event, future detection strategies need to focus on accurate quantification of genomic DNA, toxins and host response[3]. Innovative strategies including Next generation sequencing, whole metagenome shotgun sequencing, metabolome profiling is now being considered to be promising alternatives for accurate *C. difficile* detection. Combinatorial approaches like WGS with Rep-PCR differentiated the strains upto a significance accuracy of 5700 SNPs or >0.13% sequence dissimilarity between each strain[10]. An automated approach employing hot-start isothermal method with a chip based hybridization capture could detect the toxigenic *C. difficile* within an hour[11].

Strategies and methodologies incorporated in understanding the source of infection and mode of pathogenesis plays a very crucial step in early detection and proper treatment. In this era of antimicrobial resistance and polymicrobial infections, a method that caters for detection and treatment towards a specific pathogen is highly challenging. Further to this, the phenomenon of genetic mutations in the pathogens is of high concern as they tend to escape the traditional standard treatment regimes. Hence a time based-technology that amalgamates revealing both the genomic and physiological traits of the pathogen would be of much significance.

References

1. Hall, I. C., O'Toole, E. (1935). Intestinal flora in new-born infants with a description of a new pathogenic anaerobe, *Bacillus difficilis*. *American Journal of Diseases of Children*, 49, 390.
2. Rodriguez, C., Van Broeck, J., Taminiau, B., et al. (2016). *Clostridium difficile* infection: early history, diagnosis and molecular strain typing methods. *Microbial Pathogenesis*, 97, 59-78.
3. Martin, J. S., Monaghan, T. M., Wilcox, M. H. (2016). *Clostridium difficile* infection: epidemiology, diagnosis and understanding transmission. *Nature Reviews Gastroenterology & Hepatology*, 13, 206-217.
4. He, M., Sebaihia, M., Lawley, T. D., et al. (2010). Evolutionary dynamics of *Clostridium difficile* over short and long time scales. *Proceedings of the National Academy of Sciences*, 107, 7527-7532.
5. Solomon, K., Martin, A. J., O'Donoghue, C., et al. (2013). Mortality in patients with *Clostridium difficile* infection correlates with host pro-inflammatory and humoral immune responses. *Journal of Medical Microbiology*, 62, 1453-1460.
6. Vedantam, G., Clark, A., Chu, M., et al. (2012). *Clostridium difficile* infection: toxins and non-toxin virulence factors, and their contributions to disease establishment and host response. *Gut Microbes*, 3, 121-134.
7. Walker, A. S., Eyre, D. W., Wyllie, D. H., et al. (2013). Relationship between bacterial strain type, host biomarkers, and mortality in *Clostridium difficile* infection. *Clinical Infectious Diseases*, 56, 1589-1600.
8. Huber, C. A., Foster, N. F., Riley, T. V., Paterson, D. L. (2013). *Clostridium difficile* typing methods: challenges for standardization. *Journal of Clinical Microbiology*, 51, 2810-2814.
9. Eyre, D. W., Fawley, W. N., Best, E. L., et al. (2013). Comparison of multilocus variable number tandem repeat analysis and whole genome sequencing for investigation of *Clostridium difficile* transmission. *Journal of Clinical Microbiology*, 51, 4141-4149.
10. Dominguez, S. R., Anderson, L. J., Kotter, C. V., et al. (2015). Comparison of whole-genome sequencing and molecular-epidemiological techniques for *Clostridium difficile* strain typing. *Journal of the Pediatric Infectious Diseases Society*, 5, 329-332.
11. Hicke, B., Pasko, C., Groves, B., et al. (2012). Automated detection of toxigenic *Clostridium difficile* in clinical samples: isothermal *tcdB* amplification coupled to array-based detection. *Journal of Clinical Microbiology*, 50, 2681-2687.

[B]. Reckoning the dimorphic and opportunistic fungal agents of pulmonary mycoses

Rajini Kothamasuvijay Kumar^a, Peralam Yegneswaran Prakash^a

^aDepartment of Microbiology, KMC Manipal, MAHE

Fungi are eukaryotic organisms that generally are considered more useful than being harmful. Most of the medically important mycotic agents cause self-limiting diseases. Presently there are rising rates of infections in immunocompromised individuals due to the opportunistic pathogenic fungi. Pulmonary infections in immunocompetent hosts are caused by dimorphic fungi namely *Histoplasma capsulatum*, *Blastomyces dermatitidis*, *Coccidioides immitis*, *Paracoccidioides brasiliensis* and *Talaromyces marneffe* (formerly *Penicillium marneffe*).

Opportunistic mycoses are caused when the individuals have certain underlying predisposing factors whose immunological defenses are weakened in conditions like cancer, AIDS, organ transplantation and immunosuppressive therapies. The opportunistic pulmonary fungal infections account for higher rates of morbidity and mortality in hospitalized patients. The opportunistic pulmonary infections are caused by *Aspergillus* spp., *Candida* spp., *Cryptococcus* spp., *Rhizopus*, *Mucor*, *Fusarium* spp. Fungi with low virulence such *Schizophyllum* commune has been implicated in respiratory mycoses. Pulmonary fungal infections are readily diagnosed by cytology. They must be suspected whenever there is necrosis or granulomatous inflammation. Most of the fungi have a characteristic microscopic appearance that enables a faster specific diagnosis with appropriate suspicion. Due to lack of awareness most of the pulmonary fungal infections go undiagnosed. Some of the important pulmonary mycoses are highlighted further. *Histoplasma capsulatum* is the commonest cause followed by *H. duboisii* and *H. farciminosi*. The disease can mimic tuberculosis clinically, in that peripheral nodular lesions and mediastinal lymphadenopathy are relatively common. It can be presented as Acute, Subacute or chronic disease. Acute Pulmonary Histoplasmosis resembles influenza like illness (Cave Disease). Chronic pulmonary disease presents with hemoptysis and apical or subapical cavities. Reactivation Histoplasmosis occurs in patients with serious underlying disease. Pulmonary blastomycosis occurs either as an acute or chronic pyrogranulomatous systemic fungal infection of lungs with potential to disseminate to other organs. It is caused by 3 species of the genus *Blastomyces* namely; *B. dermatitidis*, *B. gilchristii* and *B. percursoris*. Acute cases are usually asymptomatic and chronic cases resemble pulmonary tuberculosis or bronchogenic carcinoma.

Coccidioidomycosis is primarily a fungal infection of respiratory system of humans and other animals. It is primarily caused by *Coccidioides immitis*. It is usually self-limiting condition but can also cause lung cavities or coccidioidoma as chronic pulmonary residual lesions. Pulmonary manifestations of paracoccidioidomycosis occurs as subacute, acute or chronic granulomatous systemic fungal infection. Most common species include: *P. brasiliensis*. It can be acute (juvenile), chronic (adult) or quiescent (latent).

Disease	Fungal etiology	Microscopic appearance	Culture Characteristics	Differential Diagnosis
Histoplasmosis	<i>Histoplasma capsulatum</i>	2-4µm small oval yeast cells.	25°C - Mycelial growth 37°C-Yeast growth	<i>T. marneffei</i> , <i>C. glabrata</i> , <i>B. dermatitidis</i> , <i>Coccidioides</i> spp.
Blastomycosis	<i>Blastomyces dermatitidis</i>	Characteristic double-contoured, thick-walled, multi-nucleated yeast forms with single broad based budding daughter cells.	25°C - Mycelial growth 37°C- Yeast form with broad based budding	<i>H. capsulatum</i> , <i>C. immitis</i>
Coccidioidomycosis	<i>Coccidioides immitis</i>	Doubly refractile thick walled globular spherules of about 20-80 µm. Immature spherules are smaller and without endospores.	25°C & 37°C - Mold form with arthroconidia	<i>Rhinosporidium seeberi</i> , <i>B. dermatitidis</i> , <i>C. neoformans</i>
Paracoccidioidomycosis	<i>Paracoccidioides brasiliensis</i>	Round refractile yeast cells of 2-10 µm size.	25°C - Mycelial growth 37°C - Yeast form showing multiple budding yeast cells.	<i>H. capsulatum</i> , <i>S. schenckii</i>

Invasive aspergillosis is by far the most common opportunistic mold causing pulmonary infection. *Aspergillus fumigatus* is the most common among them followed by *Aspergillus flavus*. The common manifestations include: Allergic Bronchopulmonary Aspergillosis (ABPA), Aspergilloma and Invasive Aspergillosis. The diagnosis of invasive pulmonary aspergillosis has been a persistent challenge. Among a number of recent developments in the diagnosis of pulmonary aspergillosis the most important of one is the assay for the detection of *Aspergillus* galactomannan in serum and BAL fluid. Pulmonary Cryptococcosis often remain indolent and is a condition caused by *Cryptococcus neoformans*. Patients may present as asymptomatic pneumonitis and pleural effusion and hilar adenopathy are uncommon and calcification is very rare. Currently, there are an increasing number of cases reported by *C. gattii*. Approximately 75% of pulmonary mucormycosis cases are caused by three genera namely *Rhizopus*, *Mucor* and *Rhizomucor*. Pulmonary mucormycosis occurs in patients who have the most profound degree of immune dysfunction, especially those who have a hematological malignancy complicated by prolonged neutropenia. Other important mycoses of lung include pulmonary candidiasis caused by *C. albicans*, Talaromycosis usually caused by *T. marneffe*, pulmonary fusariosis caused by *F. graminearum*

References

1. Smith JA, Kauffman CA. Pulmonary fungal infections. *Respirology* 2012;17:913-26.

2. Chong S, Lee KS, Chin AY, Chung MJ, Kim TS, Han J. Pulmonary fungal infection: imaging findings in immunocompetent and immunocompromised patients. *Eur J Radiol* 2006; 59:371-83.

[C]. Unusual Spontaneous Candida parapsilosis sensu lato Peritonitis

Shipra Rai^a, Peralam Yegneswaran Prakash^b, Siddharth Mahajan^a, Kavitha Saravu^a

^aDepartment of Medicine, KMC Manipal, MAHE

^bDepartment of Microbiology, KMC Manipal, MAHE

Introduction

Spontaneous fungal peritonitis in cirrhotic patients is relatively uncommon. We present an extremely rare case of spontaneous *Candida parapsilosis* peritonitis in the absence of any preceding invasive procedures.

Case

A 45-year-old man with history of alcoholic liver cirrhosis and portal hypertension presented to the hospital with altered sensorium, increasing abdominal distension and high-grade fever spikes. The patient was on long term norfloxacin antibiotic prophylaxis. On examination, patient was febrile, tachycardic, with decreased systemic blood pressure. Abdominal examination revealed diffuse tenderness and free ascitic fluid. Signs of liver failure were present and neurological examination demonstrated features of hepatic encephalopathy.

On admission, investigations revealed white blood counts of 13,200/mm³, platelet counts of 86,000/mm³, prothrombin time of 17.7 seconds with an international normalized ratio of 1.66 and deranged renal function tests. Serum total bilirubin was found to be 8.1 mg/dl with direct bilirubin of 5.4 mg/dl. Based on the clinical and laboratory findings, a diagnosis of spontaneous bacterial peritonitis and sepsis were made and the patient was started on antibiotics (Piperacillin/Tazobactam) with anti-encephalopathic measures. Ascitic fluid analysis exhibited yellow colored fluid with 0.1 gm/dl of albumin, 138 mg/dl of glucose, white blood cells counts of 259 cells/cu.mm; 63% lymphocytes, 37% neutrophils. As fever continued unabated after 5 days, patient was initiated on teicoplanin and meropenem while awaiting cultures. Blood culture was sterile and ascitic fluid culture on sabourauds dextrose agar grew yeast-like fungi with microscopic examination revealing oval budding yeast cell morphology (Figure 1) which was later identified as *C. parapsilosis sensu lato*. Despite being treated with caspofungin for the same, patient deteriorated, developed septic shock and succumbed.

Discussion

In literature, described cases of *C. parapsilosis* have been associated with low mortality and favorable outcomes. Chen CY et al. in his study has described a series of cases infected with *C. parapsilosis* responding well to antifungals especially itraconazole, posaconazole, amphotericin B and micafungin and had 30 days mortality of 25%[1]. In patients with recurrent peritoneal dialysis, *C. parapsilosis*infection is common and has been described [2]. Although infection is common with invasive procedure, no case of spontaneous *C. parapsilosis* peritonitis has been described in literature. In this case, ascitic fluid exhibiting lymphocytic predominance was a clue against bacterial peritonitis and a pointer towards fungal or a tubercular process.

Table 1 : Current regimens for treatment of intraabdominal candidiasis adopted from IDSA guidelines, 2016 [3-4]
<ul style="list-style-type: none">• Testing for azole should be considered in all patients of candidemia. Testing for echinocandin susceptibility should be considered in patients who have had prior treatment with an echinocandin and among those who have infection with <i>C. parapsilosis</i>.
<ul style="list-style-type: none">• An echinocandin (caspofungin: loading dose 70 mg, then 50 mg daily; micafungin: 100 mg daily; anidulafungin: loading dose 200 mg, then 100 mg daily) is recommended as initial therapy.
<ul style="list-style-type: none">• Fluconazole 800 mg as a loading dose, followed by 400mg/d of fluconazole as a maintenance dose for at least 2 weeks after clinical improvement or negative blood cultures is an acceptable alternative to an echinocandin.
<ul style="list-style-type: none">• Lipid formulation AmB (3-5 mg/kg daily) is a reasonable alternative if there is intolerance, limited availability, or resistance to other antifungal agents like azoles and echinocandins.
<ul style="list-style-type: none">• Voriconazole 6 mg/kg intravenously or orally twice per day, followed by 3 mg/kg orally twice per day or 200 mg orally twice per day is a less attractive alternative to flucanazole.
<ul style="list-style-type: none">• Transition from an echinocandin to fluconazole (usually within 5-7 days) is recommended for patients who are clinically stable, have isolates that are susceptible to fluconazole and have negative repeat blood cultures following initiation of antifungal therapy.
<ul style="list-style-type: none">• Transition from Amphotericin B to fluconazole is recommended after 5-7 days among patients who have isolates that are susceptible to fluconazole, who are clinically stable, and in whom repeat cultures on antifungal therapy are negative.

Table 1 depicts the review on current regimens for treatment of candidemia. Unlike other cases of *Candida* spp. if *C. parapsilosis* suspected, patient (especially high risk) should be intensely treated early with antifungals. Treatment of intra-abdominal candidiasis should include source control, with appropriate drainage and/or debridement[3]. Recent observational data from Spain among almost 200 patients with candidemia due to *C. parapsilosis* suggested no difference in outcome among patients who received initial treatment with an echinocandin compared with those who received other regimens[5]. Empiric antifungal therapy should be considered in critically ill patients with risk factors for invasive candidiasis and no other known cause of fever [3]. Cases attributed to spontaneous *C. parapsilosis*peritonitis have not been commonly reported in the literature. It is thus recommended that further research needs to be undertaken to assess the specific efficacy and outcomes of the echinocandins, along with alternate drug therapies in order to develop guidelines for this specific subspecies of *Candida* in patients with renal/hepatic dysfunction.

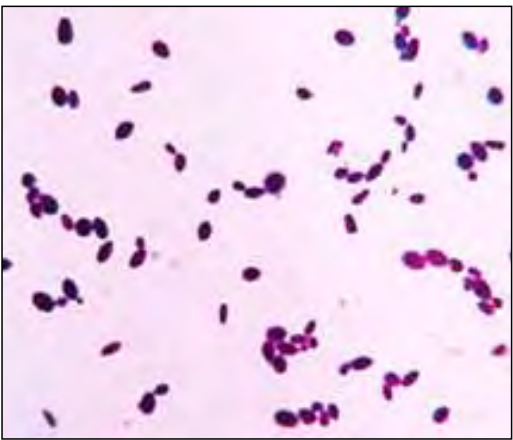


Figure 1: Microscopic morphological features of *Candida Parapsilosis* as seen under gram stained smear 100x showing; budding and elongated single blastoconidial forms with sizes varying from 2-5µm×3-7µm

References:

1. Chen CY, Sheng WH, Huang SY, et al. Clinical characteristics and treatment outcomes of patients with candidaemia due to *Candida parapsilosis* species at a medical centre in Taiwan, 2000-12. *J Antimicrob Chemother.* 2015,

2. Trofa D, Gácser A, Nosanchuk JD. *Candida parapsilosis*, an Emerging Fungal Pathogen. *Clinical Microbiology Reviews.* 2008;21(4):606-625.

3. Pappas PG, Kauffman CA, Andes D, et al. Clinical practice guidelines for the management of candidiasis: 2016 update by the Infectious Diseases Society of America. *Clin Infect Dis.* 2016;civ933.

4. Sobel JD, Revankar SG. Echinocandins--first-choice or first-line therapy for invasive candidiasis?. *N Engl J Med.* 2007;356(24):2525-6.

5. Mario Fernández-Ruiz, José María Aguado, Benito Almirante, David Lora-Pablos, Belén Padilla, Mireia Puig-Asensio, Miguel Montejo, Julio García-Rodríguez, Javier Pemán, Maite Ruiz Pérez de Pipaón, Manuel Cuenca-Estrella, for the CANDIPOP Project, GEIH-GEMICOMED (SEIMC), and REIPI; Initial Use of Echinocandins Does Not Negatively Influence Outcome in *Candida parapsilosis* Bloodstream Infection: A Propensity Score Analysis, *Clinical Infectious Diseases* 2014, 1413–1421.

[D]. Massive haemoptysis due to obscure aetiology- perils and management dilemmas

Shreenivasa A^a, Vishak K A^a, Sindhu K^a, Kauslya Sahu^b

^aDepartment of Pulmonary Medicine, KMC Mangaluru, MAHE

^bDepartment of Pathology, KMC Mangaluru, MAHE

Abstract:

Pulmonary Actinomycosis is an important differential diagnosis in patient with long-standing pulmonary infiltrates related to poor oral hygiene or compromised immune function. Up to a quarter of cases of thoracic actinomycosis are misdiagnosed as lung malignancy. Here we report a 56-year-old man with a hypodense lesion in the left lower lobe presenting with recurrent massive haemoptysis for about one year. He underwent left lower lobe lobectomy due to intractable haemoptysis. Histopathological examination demonstrated actinomycosis infiltrating the left lower lobe. Rarity of the case was presence of actinomycosis in an immunocompetent individual and without underlying pre-existing lung disease. Also, intractable massive haemoptysis necessitating surgical excision which proved to be both diagnostic and curative due to actinomycosis is an unusual occurrence.

Introduction:

Actinomycosis is an uncommon, chronic, and slowly progressive bacterial infection caused by gram positive anaerobic bacteria, belonging to the family actinomycetaceae[1]. Human form of actinomycosis associated with suppurative and granulomatous inflammation characterized by swelling, sinus tract formation, and purulent discharge containing yellowish sulfur granules[2]. Pulmonary actinomycosis accounts for 15-20% total incidence of actinomycosis[3]. Actinomyces are thought to colonize devitalized tissues so higher incidence of pulmonary actinomycosis has been reported in patients with underlying lung disorders, such as emphysema, chronic bronchitis, and bronchiectasis[4].

Pulmonary actinomycosis is caused by aspiration of oropharyngeal or gastrointestinal secretions into the respiratory tract. Pulmonary actinomycosis usually presents with chest pain, productive cough, and dyspnea[5]. Pulmonary actinomycosis is rarely included in the differential diagnosis of a patient with a pulmonary infiltrates[6] with most patients being investigated for other possible diseases, before the final diagnosis is made.

Case Report:

A 53-year-old male, smoker (20 pack years), occasional alcoholic presented with complaints of recurrent haemoptysis with 4-5 bouts of massive haemoptysis requiring hospitalizations and emergency care since 9 months. He denied history of fever, chest pain, and loss of appetite. He had undergone cholecystectomy 3 years ago. There was no history of systemic immune suppression like diabetes. He had undergone bronchial artery embolization for massive haemoptysis, however his haemoptysis persisted and diagnosis remained elusive after evaluation with sputum studies, and CT guided aspiration cytology, biopsy and bronchoscopic lavage. He was treated for LRTI with multiple courses of antibiotics for more than 9 months.

On examination vitals were normal with no respiratory distress. Oral hygiene was poor with dental caries. Respiratory examination revealed scattered crackles in left lower lobe area. Chest X-ray showed an in-homogenous opacity in left lower zone with raised left diaphragm and CECT (Contrast enhanced computer tomogram) chest showed a hypodense lesion with irregular margins in anterior segment of left lower lobe adjacent to descending aorta and associated subcarinal lymphadenopathy (Figure 1 and 2). Image guided transthoracic biopsy showed type 2 alveolar cell hyperplasia with negative immunohistochemistry. Bronchoscopy confirmed left lower lobe bleed with an endoluminal lesion. Bronchial wash was negative for microbiological and cytological study including AFB stain, gene Xpert for MTB complex and Pyogenic culture. Patient's symptoms of haemoptysis persisted; hence CT angiogram was done which showed dilated vascular channels within the lesion without any obvious extravasations of contrast and no aortic abnormality.

Probable diagnosis of left intrapulmonary vascular lesion was made and patient underwent left lower lobe lobectomy. Intra operatively, left lower lobe was adherent posterolaterally to aorta and diaphragm. Multiple prominent blood vessels in areas of adhesion were seen. Histopathology was suggestive of chronic inflammatory cells with focal aggregates of lymphocytes with positive GMS staining for actinomycosis. Post operatively parenteral benzyl penicillin 20 lakh units 6th hourly was given for 3 months. Patient is on regular follow up, there has been no further episodes of hemoptysis and no recent respiratory complaints.

Discussion:

Pulmonary actinomycosis is seen at all ages, commonly in adults and peak incidence described in the 4th and 5th decade[7]. In recent years with the improvement in oral hygiene, and early use of antibiotics, the presentation of pulmonary actinomycosis has changed from aggressive to less aggressive making diagnosis more difficult[8]. Clinical manifestations of pulmonary actinomycosis are variable although cough and sputum are the most common symptoms[9]. Hemoptysis though not common, has been reported often in pulmonary actinomycosis[2] and may be explained by underlying structural diseases such as bronchiectasis. The disease usually affects lower lobe[10], probably reflecting the role of aspiration in its pathogenesis. Pulmonary actinomycosis is usually characterized by fibrotic lesion which is slowly progressive through the anatomical barriers which is often confused with malignancy[1].

Pulmonary actinomycosis shares many similar clinical features with chronic suppurative lung infections such as tuberculosis, fungal infections and lung abscesses, and also lung malignancy with which it is frequently confused. Culture of bacteria from the sputum or bronchoalveolar secretions is technically difficult[11] and also sometimes it represents colonization of non pathological microorganisms[12] confirmation of the diagnosis of pulmonary actinomycosis usually requires lung biopsy[10].

Pulmonary actinomycosis may present as masses, nodules, patchy infiltrates and solitary lesion[8]. A CT chest or ultrasound guided biopsy is usually recommended prior to the surgical biopsy. However, the CT guided biopsies may not be diagnostic as reported in our case. There also could be a case for percutaneous aspirated to be sent for cultures routinely along with cytology to improve diagnostic accuracy. Thus, the gold standard for diagnosis of thoracic actinomycosis is a histological confirmation on lung biopsy.

Most cases of pulmonary actinomycosis have been diagnosed from post-surgical specimens taken on suspicion of lung cancer[1] as done in our case. Due to inadvertent use of antibiotics and non-specific clinical presentations makes pulmonary actinomycosis difficult to be diagnose and often leads to misdiagnosis as malignancy rather than an infective disease[13]. Co-existence of lung cancer with pulmonary actinomycosis results in a diagnostic challenge[14]. Reduction of alcohol abuse and improvement of dental hygiene may limit the occurrence of pulmonary actinomycosis[1] and require prolonged high doses of antimicrobial therapy with beta-lactam antibiotics for about 6 - 12 months[1].

In conclusion, this case is remarkable not only for the development of pulmonary actinomycosis in an immunocompetent patient, but also for associated recurrent massive haemoptysis which eluded diagnosis and finally resection surgery confirmed the diagnosis and also was curative.

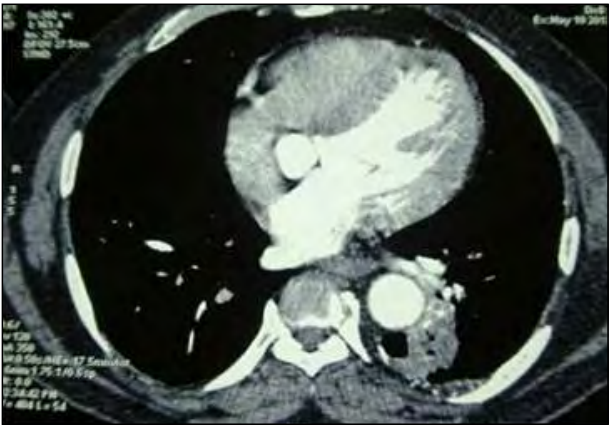


Fig 1: Irregular margin air space consolidation with cavitations seen in left anterior segment adjacent to descending aorta.

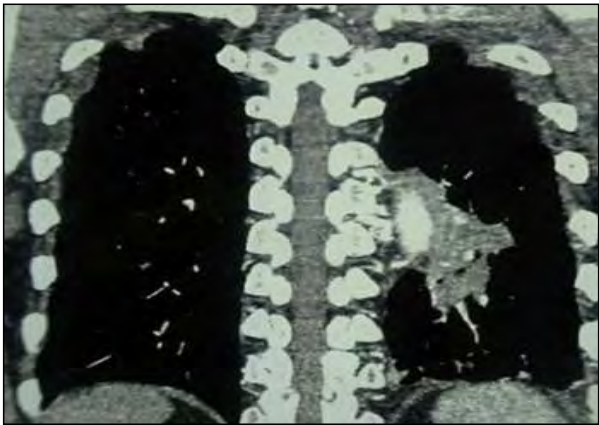


Fig 2: An irregular mass is seen on left lower lobe adjacent to aorta with pleural involvement.

References:

1. Valour F, Sénéchal A, Dupieux C, Karsenty J, Lustig S, Breton P, et al. Actinomycosis: Etiology, clinical features, diagnosis, treatment and management. *Infect Drug Resist* 2014; 7:183-97.
2. Kim, S.R., Jung, L.Y., Oh, IJ. et al. *BMC Infect Dis* 2013 ;13: 216.
3. Wong VK, Turmezei TD, Weston VC. Actinomycosis. *BMJ* 2011; 343: d6099.
4. Mabeza GF, Macfarlane J. Pulmonary actinomycosis. *EurRespir J* 2003; 21:545-51.
5. Kim TS, Han J, Koh WJ, Choi JC, Chung MJ, Lee JH, Shim SS, Chong S: Thoracic actinomycosis: CT features with histopathologic correlation. *AJR Am J Roentgenol*. 2006, 186 (1): 225-231. 10.2214/AJR.04.1749.
6. T.M. Alfaro J. Bernardo H. Garcia F. Alves, L. Carvalho, Caseiro Alves, RobaloCordeiro. Organizing Pneumonia due to Actinomycosis: An Undescribed Association. *Respiration* 2011; 81:433–436 .
7. Heffner JE. Pleuropulmonary manifestations of actinomycosis and nocardiosis. *SeminRespir Infect* 1988; 3:352-61.
8. Xue-Feng Sun, Peng Wang, Hong-Rui Liu, Ju-Hong Shi. A Retrospective Study of Pulmonary Actinomycosis in a Single Institution in China. *Chinese Medical Journal* 2015.
9. Kwong JS, Muller NL, Godwin JD, Aberle D, Grymaloski MR: Thoracic actinomycosis: CT findings in eight patients. *Radiology*. 1992, 183 (1): 189-192.
10. Ahmed Fahim, Richard Teoh, Jack Kastelik, Anne Campbell, Damian McGivern , Case series of thoracic actinomycosis presenting as a diagnostic challenge; *Respiratory Medicine CME* (2009) 2, 47e50

11.Wong RH, Sihoe AD, Thung KH, Wan IY, Ip MB, Yim AP. Actinomycosis: an often forgotten diagnosis. AsianCardiovascThorac Ann. 2004 Jun; 12(2):165-7.

12. Ariel I, Breuer R, Kamal NS, Ben-Dov I, Mogel P, RosenmannEEndobronchialactinomycosis simulating bronchogenic carcinoma. Diagnosis by bronchial biopsy. Chest. 1991 Feb; 99(2):493-5.

13. Qiu L, Lan L, Feng Y, Huang Z, Chen Y. Pulmonary Actinomycosis Imitating Lung Cancer on 18F-FDG PET/CT: A Case Report and Literature Review. Korean Journal of Radiology. 2015;16(6):1262-1265. .

14. Charif F, Harb A, Alifano M, Giraud F, Rabbat A, Huchon G, Roche N .Bronchial carcinoma and actinomycosis: a dangerous trap;Rev Mal Respir. 2009 Nov; 26(9):1003-6.

[E]. A case of pulmonary mucormycosis

Raghavendra Rao S^a, Rama Bhat^a
^aDepartment of Medicine, KMC Manipal, MAHE

Case :

A 38 year old male was admitted with left side facial pain and swelling of 3 weeks duration and cough with expectoration (blackish sputum) of 1 week duration. He had high grade fever and nasal discharge. There was no history of breathlessness, chest pain or night sweats. He had no past history of diabetes, tuberculosis or asthma. On examination he was febrile, vitals were normal and had left sided facial swelling. On respiratory system examination, he had slightly reduced chest movements on right side with cavernous type of bronchial breathing in right mammary area. Other systemic examination findings were normal. He was investigated for the same, he had high total leucocyte count (20,800/ μ l) with neutrophilia. He was also diagnosed to have diabetes mellitus with ketoacidosis. Sputum culture and staining for acid fast bacillus was negative. X-ray of the paranasal sinus was suggestive of left maxillary sinusitis and chest x-ray revealed cavities in both lungs. Contrast enhanced CT of thorax was done which showed cavities with peripheral consolidation in right upper lobe and left lower lobe. Functional endoscopic sinus surgery (FESS) was done and histopathology of left maxillary sinus tissue specimen revealed invasive mucormycosis with maxillary bone osteomyelitis. Bronchoscopic lavage fluid was sent for analysis which showed typical hyphae of mucormycosis. He was treated for diabetic ketoacidosis with normal saline and intravenous insulin infusion. Amphotericin-B emulsion was started at a dose of 5mg/kg/day for pulmonary and sinus involvement of mucormycosis. After 7 days of treatment he had worsening of chest symptoms and later succumbed to the disease.

Discussion:

Fungi of the Mucor genus are conditional pathogens that rarely cause disease in healthy individuals. However, inhalation of these spores may result in disease in subjects with impaired immune function[1]. The organisms spread through the paranasal sinuses and respiratory system, or by the hematogenous or lymphatic route[2]. The majority of patients with mucormycosis present one or more risk factors, including hematopoietic malignancies, treatment with immune inhibitors or diabetes mellitus. In addition, a low neutrophil count is an independent risk factor for Mucor infection[3]. Pulmonary mucormycosis accounts for ~25% of cases of mucormycosis, followed by nasal and brain mucormycosis. Furthermore, pulmonary mucormycosis has a fatality rate of >50%[4]. The clinical manifestations are non-specific and commonly include fever, cough, chest pain, dyspnea and hemoptysis, since these pathogens can erode blood vessels[5]. Radiological manifestations include infiltrates, exudation, consolidation, cavities and nodules, while the disease typically has a predilection for the upper lobes[6]. Our patient presented with cavities in the lung which was present in upper as well as lower lobe. The disease also was of subacute onset and he had presented with diabetes ketoacidosis. He had not responded to the empiric antibiotic therapy which was started. Therefore, in cases where antibiotic treatment is ineffective and the patient has an underlying disorder, unusual pulmonary infections such as mucormycosis should be considered. The gold standard

for the diagnosis of pulmonary mucormycosis is the finding of characteristic hyphae and pathologic changes in a biopsy specimen. The sensitivity of microscopic examination of sputum and sputum culture is low, and the false positive rate is high[7]. The majority of published studies state that liposomal amphotericin B is effective against pulmonary mucormycosis[8]. In the present case, amphotericin B emulsion was used rather than the liposomal form due to financial constraints. Patient was also on intravenous infusion of insulin for diabetic ketoacidosis which was later changed to subcutaneous insulin. However patient succumbed to the disease.

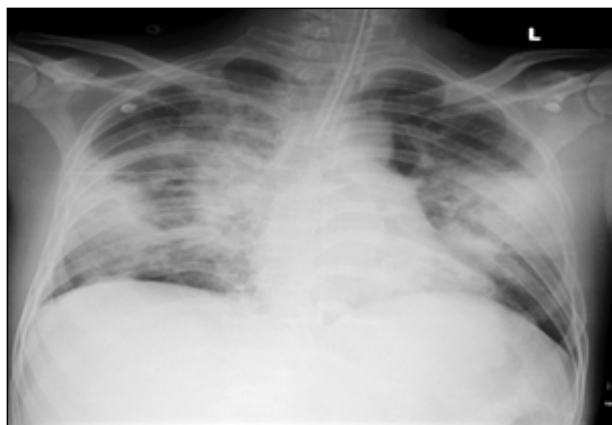


Fig 1: Chest X-ray PA view showing cavities in both lungs

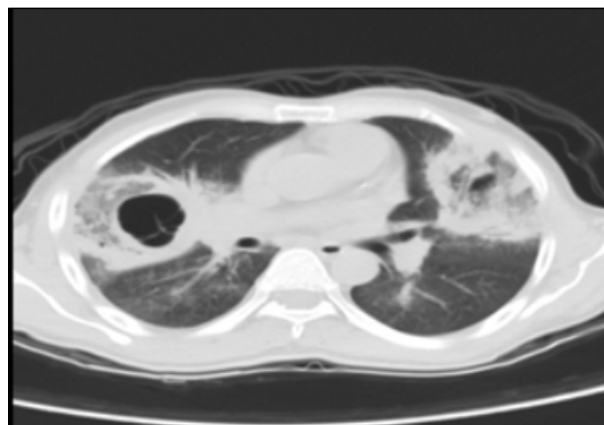


Fig 2 : CECT Thorax showing thick walled cavities with consolidation

References :

1. Skiada A, Pagano L, Groll A, Zimmerli S, Dupont B, Lagrou K, Lass-Florl C, Bouza E, Klimko N, Gaustad P, et al. Zygomycosis in Europe: Analysis of 230 cases accrued by the registry of the Europe confederation of medical mycology (ECMM) working group on zygomycosis between 2005 and 2007. *ClinMicrobiol Infect.* 2011;17:1859–67.
2. Yang Y, Fang B, Xu X, Fang F, Pan M, Zhong X, Sun T. Pulmonary mucormycosis: report of 5 cases and review of 46 cases reported in China. *Chin J TubercRespir Dis.* 2013;36:572–6.
3. Roden MM, Zaoutis TE, Buchanan W1, Knudsen TA, Sarkisova TA, Schaufele RL, Sein M, Sein T, Chiou CC, Chu JH, et al. Epidemiology and outcome of zygomycosis: A review of 929 reported cases. *Clin Infect Dis.* 2005;41:634–53
4. Spellberg B, Kontoyiannis DP, Fredricks D, Morris MI, Perfect JR, Chin-Hong PV, Ibrahim AS, Brass EP. Risk factors for mortality in patients with mucormycosis. *Med Mycol.* 2012;50:611–8.
5. Liang Z, Jin F, She D, Chen L. Clinical analysis of 5 patients with pathologically diagnosed pulmonary mucormycosis. *J ClinPulm Med.* 2012;418–9.
6. Yang C, Xie X. Diabetes and Nose-Cerebral Mucormycosis: A Case Study. *ShiyongYiyuanLinchuanZachi.* 2015;12:183–4
7. The Subspecialty Group of Infectious Diseases, Society of respiratory, Chinese Medical Association, Editorial board of Chin J TubercRespir Dis: Specialist Consensus of Diagnosis and Treatment on Pneumonomycosis. *ZhonghuaJiHe He HuxiZachi.* 2007;30:821–34.

[F]. Huge fungal perinephric abscess masquerading as malignancy

Sharath Madhyastha P^a, Raviraja V Acharya^a, Barnini Banerjee^b, Prakashini K^c

^aDepartment of Medicine, KMC Manipal, MAHE

^bDepartment of Microbiology, KMC Manipal, MAHE

^cDepartment of Radio-diagnosis, KMC Manipal, MAHE

Abstract:

Invasive candidiasis is increasingly important nosocomial infection, especially in ICU settings. *Candida albicans* is the most common species associated with invasive candidiasis. Recently there is increased isolation of non albican candida. Here we are reporting a case of disseminated *Candida kefyr* infection which presented to us masquerading as abdominal malignancy.

Case Report:

A 60-year-old women diabetic, hypertensive for the past 15 years, with two episodes of complicated urinary tract infection in last 6 months treated with broad spectrum antibiotics (imipenem) in local hospital, presented with complains of fever, vomiting, loin pain and breathlessness. On examination, she had tachycardia, tachypnea, hypotension (BP of 90/60 mm of Hg), O₂ saturation of 84% on room air, decreased breath sounds on left hemi thorax and a large non tender, palpable mass on left lumbar region of abdomen, measuring around 10 x 10cm.

On evaluation, she had anemia (Hb - 8.4g/dL), polymorphonuclear leukocytosis of 22750 cells/mm³ and thrombocytosis. Serum creatinine was 5.1 mg/dL. Urine microscopy showed full field of WBCs, and yeast cells. Random blood sugar was 283 mg/dL at admission with glycated hemoglobin of 13.8%. Patient was started on empirical broad spectrum antibiotics (Meropenem with modified dose according to creatinine clearance) after sending blood (in a BacT/ALERT® FA Plus bottle) and urine for culture and antibiotic susceptibility testing. She was supported with inotropes, mechanically ventilated and received one session of hemodialysis. Chest x ray was suggestive of left massive pleural effusion. Pleural fluid aspiration showed neutrophilic exudative pleural fluid (total count of 18500 cells/mm³, 99% neutrophils, protein- 3.4 g/L, LDH 1814 IU/L, serum total protein 6.5 g/L, serum LDH 581 IU/L). Non contrast CT KUB [Figure 1 and 2] showed a large heterogeneous lobulated collection 8.6*6.5*10.3 cm in the perinephric region which was drained with Image guided pig tail insertion and the aspirate was also sent for culture. Both the BacT bottle signaled positive for *Candida kefyr*. In urine it was 10,000 colony forming unit/ml and in the pleural fluid and perinephric collection there was a heavy growth of *C. kefyr*. The *C. kefyr* was identified by Matrix Assisted Laser Desorption Ionization Time-of-Flight (MALDI-TOF) VITEK®MS and antimicrobial susceptibility testing for the isolates was done by VITEK®2 system (bioMérieux, Inc, Durham, NC). The isolated *Candida kefyr* was sensitive to echinocandins, amphotericin, and fluconazole. But patient had septic shock which was refractory and succumbed to the illness within 48 hours of hospital stay.

Discussion:

Candida kefyr, previously called as *Candida pseudotropicalis*, was first reported by Morgan MA et al,[1] in an elderly female with malignancy. Subsequently there are case reports of candida esophagitis, enteritis, isolation from pleural fluid, neonatal candidemia. *C. kefyr* is a rare cause of disease. Among 2019 patients with invasive fungal infections reported from North America between 2004 and 2008, 11 isolates were *C. kefyr*[2]. This is the first reported case of disseminated *Candida kefyr* from eastern part of the world.

Risk factors for candida urinary traction infection are diabetes, urinary tract abnormalities, malignancy, urinary tract drainage devices and prior antibiotic therapy[3]. Our patient had uncontrolled diabetes with glycated hemoglobin of 13.3%, prior use of broad spectrum antibiotics twice. Among the previous 13 reported cases, most common risk factors were underlying malignancy or immunosuppression.

Our isolate was sensitive to all the three drug groups. But our patient presented late, and received only one dose of antifungals, so it is difficult to make any conclusions of antifungal efficacy in our case. In 10.5 year worldwide surveillance study, [4] resistance to fluconazole for candida kefyr ranged from 3.3% to 1.7 % in different time period, 1997-2000 and 2005 -2007 respectively.

In conclusion, with increasing use of antifungal prophylaxis, higher incidence of isolation of non-candida albicans and emergence of azole resistance, knowledge about emerging pathogens and antifungal sensitivities is of importance.

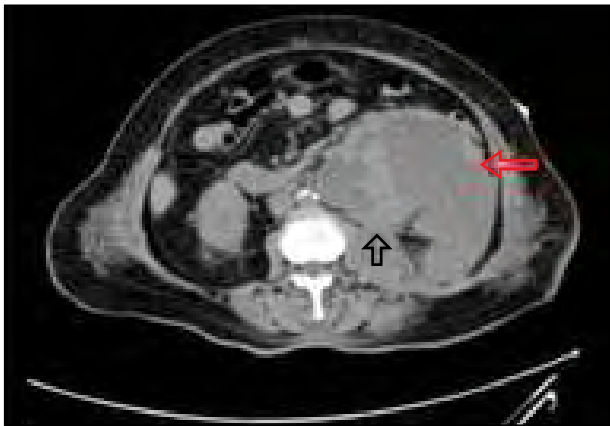

Figure 1: Axial image of plain CT KUB showing large heterogeneous lobulated collection (red arrow) in the left perinephric and paranephric space causing indentation and medial displacement of kidney and collection is extending up to the left psoas muscle (black arrow).

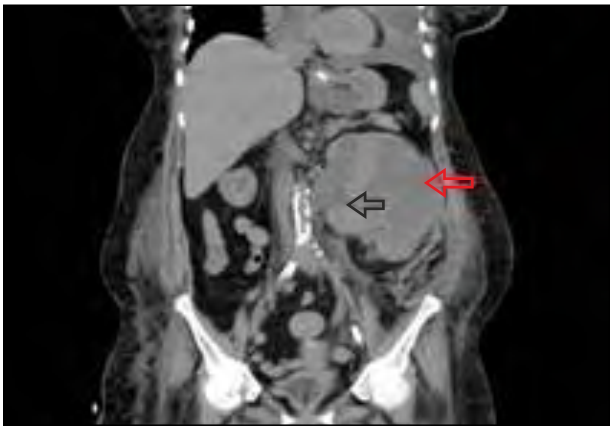


Figure 2: Coronal image of plain CT KUB showing left perinephric abscess (red arrow) with moderate hydronephrosis (black arrow) with abrupt termination at PUJ which possibly represents PUJ obstruction secondary to stricture. Also note there is moderate to gross left pleural effusion.

References:

1. Morgan MA, Wilkowske CJ, Roberts GD. Candida pseudotropicalis fungemia and invasive disease in an immunocompromised patient. J Clin Microbiol 1984; 20:1006-7.
2. Horn DL, Neofytos D, Anaissie EJ, et al. Epidemiology and outcomes of candidemia in 2019 patients: data from the prospective antifungal therapy alliance registry. Clin Infect Dis 2009; 48:1695.
3. Kauffman CA, Vazquez JA, Sobel JD, et al. Prospective multicenter surveillance study of funguria in hospitalized patients. The National Institute for Allergy and Infectious Diseases (NIAID) Mycoses Study Group. Clin Infect Dis 2000; 30:14.
4. Pfaller MA, Diekema DJ, Gibbs DL, et al. Results from the ARTEMIS DISK Global Antifungal Surveillance Study, 1997 to 2007: a 10.5-year analysis of susceptibilities of Candida species to fluconazole and voriconazole as determined by CLSI standardized disk diffusion. J Clin Microbiol 2010; 48:1366-77.

[G]. Rapid Progressive Dementia with Encephalitis – A Post-Dengue Complication

Afsal PM^a, Arvind Prabhu^b, Avinash Koraddi^a, Shashikiran Umakanth^a

^aDepartment of Medicine, Dr. TMA Pai Hospital, Udupi, MMMC, MAHE, Manipal

^bDepartment of Neurology, KMC Manipal, MAHE, Manipal

Case Report:

An 84-year-old lady, known hypertensive, presented with rapidly progressive dementia, and delayed episodic cognitive disturbances for ten days. She was normal until a month earlier when she had serologically proven uncomplicated dengue fever and recovered with conservative management.

She developed episodes of lethargy, sleepiness, and cognitive disturbances with progressive dementia approximately three weeks after recovering from dengue fever.

Metabolic screening and magnetic resonance imaging (MRI) of the brain were performed to identify the cause. All the tests were within normal limits. Supportive management was done, but her symptoms continued to worsen. She was evaluated further with video electroencephalogram (EEG), lumbar puncture with cerebrospinal fluid (CSF) analysis and autoimmune workup including VGKC (voltage-gated K⁺ channel), NMDA (N-methyl D-aspartate) and GAD (glutamic acid decarboxylase) antibody panels were sent to NIMHANS Bangalore. Video EEG showed moderate to severe encephalopathy with left temporal spikes, suggestive of seizure activity. CSF studies were normal. The entire autoimmune panel was reported negative. A repeat MRI brain, about a week later, was also normal.

Given the abnormal EEG, anti-epileptic drugs were started. Though antinuclear antibodies and CNS autoantibodies were negative, intravenous dexamethasone was given, considering a post-infectious immune-mediated disease. Her consciousness and seizure frequency improved gradually, she was able to sit with support, talk, and showed gradual improvement in cognitive function. Four weeks later, she was better, seizure-free, with improvement in cognitive function. Corticosteroids were gradually tapered and stopped.

Discussion

In this patient, a post-infectious immune-mediated disease was suspected after excluding all other causes of rapidly progressive dementia and seizures. Neurological signs were first reported in 1976 as atypical symptoms of dengue infection[1]; their incidence rates varied from 0.5 to 20% in recent years[2]. Neurological manifestations of dengue have been reported in 25 countries spanning almost all continents [3].

There are descriptions of neurological complications of dengue involving the central and peripheral nervous systems, and the ophthalmological system. They include encephalitis, myelitis, seizures, myositis, and delayed immune-mediated complications including acute disseminated encephalomyelitis (ADEM), Guillain-Barré syndrome (GBS), brachial neuritis, opsoclonus, myoclonus, etc. Both direct (neurotropism) and immunological mechanisms are responsible for neurological manifestations in dengue infection. There are three possible hypotheses of pathogenic mechanisms for the neurological complication in dengue infection: (i) viral neurotropism leading to encephalitis, meningitis, myositis, and myelitis, (ii) systemic complications resulting in encephalopathy, stroke, and hypokalemic paralysis, and (iii) post-infectious immune-mediated ADEM, GBS and optic neuritis [2]. In this patient, after exclusion of other causes of rapidly progressive dementia [4], systemic autoimmune diseases and common CNS autoimmune encephalitis conditions like NMDA, VGKC and GAD antibodies, and the persistence of new-onset sub-acute seizures despite three antiepileptic drugs, the possibility of a post-infectious immune-mediated disease was considered. The patient showed recovery on empirical treatment with dexamethasone.

To the best of our knowledge, post-dengue rapidly progressive dementia with seizures has not yet been described. Post-infectious immune-mediated disorder could be a possible explanation of this syndrome in our patient.

Conclusion

Dengue can cause various neurological manifestations. Recent dengue infection should be suspected in patients presenting with neurological features without apparent causes, especially when preceded by febrile illness.

References

1. Sanguansermsri T, Poneprasert B, Phornphutkul B. Acute encephalopathy associated with dengue infection. Bangkok: Seameo Tropmed. 1976:10-11.
2. Solbrig MV, Perng GC. Current neurological observations and complications of dengue virus infection. Curr Neurol Neurosci Rep. 2015 Jun;15(6):29.
3. Verma R, Sharma P, Garg RK, Atam V, Singh MK, Mehrotra HS. Neurological complications of dengue fever: Experience from a tertiary center of north India. Ann Indian Acad Neurol. 2011 Oct;14(4):272-8.
4. Geschwind MD. Rapidly Progressive Dementia. Continuum (Minneapolis). 2016 Apr;22 (2 Dementia):510-37.

[H]. New portable malaria screening instrument

Rakshita Maskeri^a, Animesh Jain^b, Shethal Ullal^a

^aDepartment of Pharmacology, KMC Mangaluru, MAHE Mangaluru

^bDepartment of Community Medicine, KMC Mangaluru, MAHE Mangaluru

According to the World Health Organization in the year 2016, 216 million cases of malaria have been reported worldwide and caused death of 445,000 individuals[1]. Nearly 70% of deaths occurred in children aged below 5 years. Early diagnosis and treatment is essential for effective malaria treatment, control and elimination.

WHO recommends two standard ways for the diagnosis of malaria[2]. The first one is conventional microscopic examination of peripheral blood films which still remains the gold standard for the diagnosis of malaria. However, the disadvantages of conventional microscopy are the requirement of technical expertise and good-quality microscopes. The second method is Rapid Diagnostic Test which gives quick results in fifteen minutes. It has disadvantages of shelf life and may not be able to detect infection with low parasite number.

University of Southern California (USC) Viterbi engineers have made a new prototype for a portable optical diagnostics system (PODS) for diagnosis of malaria based on the presence of haemozoin, the malaria pigment [3]. It is developed for screening malaria in low-resource settings.

How it works: Asexual life cycle of the parasite occurs in humans with the host haemoglobin as a primary source of nutrition. During the maturation process the haemoglobin is digested and the free haem which is highly toxic to parasite is rendered harmless by polymerisation to haemozoin.

PODS is based on differential optical spectroscopy. It has three primary components: a laser, a detector (to detect light), and a magnet. The concentration of haemozoin present in whole blood is detected by monitoring the change in optical power before and after a magnet is applied.

The sample of blood is placed between the laser and the detector, the amount of light that reaches detector decreases as the blood blocks it. If haemozoin is present, the amount of light that reaches reduce because the nanocrystal is very good at blocking light. By applying magnetic field, the hemozoin particles are moved within a test tube away from the laser beam. In this way, a single sample can be used to perform two measurements, and every diagnosis is personalized. If haemozoin is present, the signals change.

Thus PODS operates on a very simple design concept that if haemozoin is present, then there must be malaria.

Advantages of PODS:

- This device can analyse an unprocessed, whole blood sample in 10-15 minutes.
- The device is lightweight around 4.5 kgs and smaller in size which makes it easily portable. It can be powered by a battery for eight hours.
- It requires minimal sample processing and handling. There are no strict storage requirements.
- This makes the device particularly suited low-resource environments.

References:

1. World malaria report 2017 [Internet]. World Health Organization Geneva, 2017 [cited 7 July 2018]. Available from: http://www.who.int/malaria/publications/world_malaria_report/en/
2. Guidelines for the treatment of malaria third edition [Internet]. World Health Organization 2015 [cited 7 July 2018]. Available from: <http://www.who.int/malaria/publications/atoz/9789241549127/en/>
3. McBirney S, Chen D, Scholtz A, Ameri H, Armani A. Rapid Diagnostic for Point-of-Care Malaria Screening. ACS Sensors. 2018.

3. Crossword - To Keep the Grey Matter Ticking....

5		1	2			3			4		8
						6			7		
	9						10				
			11			12					
	13					14				15	
		16									
					17						18
			19								
					20						

ROWS

- 01.Females feed on blood, males do not (9)
- 06. Autoimmune polyendocrinopathy with predisposition for candidial infections (5)
- 09. Rickettsial species causing pox (5)
- 10. Brand name of commonly used antipyretic (4)
- 11. Oral flora, difficult to grow, can produce murmurs on the chest (5)
- 13. AIDS defining illness causing virus, MRI lesions crossing midline, Alein hand syndrome (2)
- 14. Hemorrhagic fever in west Africa spread by rats (5)
- 16. ATT drug that can make a patient vampire (photosensitivity, gum atrophy, prominent canines, dark colored urine) (9)
- 17. Associated with childhood burkitts lymphoma in Africa, initially thought to be spread by bad air (7)
- 19. Raccoon eyes, huge heart, large kidneys, frothy urine (7)
- 20.E.coli and klebsiella can, Acinetobacter & Pseudomonas cannot (7)

COLUMNS

- 1. Ototoxic, nephrotoxic, have antitubercular activity (8)
- 2. Malaysia, Bangladesh, Kerala, Bats (5)
- 3. Pneumonia after 48 hrs of hospital admission (3)
- 4. Common organism causing UTI (5)
- 5. Vietnam time bomb, found in soil of Karnataka (10)
- 7. Polymyxin E (8)
- 8. Salmonella and shigella fell in love and planned to marry. Salmonella was waiting but shigella couldn't come because it is? (8)
- 10.This condition increases susceptibility to mucormycosis (3)
- 12.Test that uses antibodies and color change to identify a substance (5)
- 15.Levels of this enzyme is useful in diagnosis of tuberculosis (3)
- 18.Drugs prescribed in HIV infection (3)

(Solutions on Pg.48)
Compiled by: **Dr. Tirlangi Praveen Kumar**
Senior Resident, Department of Medicine, KMC Manipal

4. Interesting ID related articles published in 2017-18

1. Kumar AKH, Chandrasekaran V, Kumar AK, Kawaskar M, Lavanya J, Swaminathan S, et al. Food significantly reduces plasma concentrations of first-line anti-tuberculosis drugs. *Indian J Med Res* 2017 ;145(4):530-35.
2. Yadav PD, Chaubal GY, Shete AM, Mourya DT. A mini-review of Bunyaviruses recorded in India. *Indian J Med Res* 2017 ;145(5):601-10.
3. Jain S, Mittal A, Sharma SK, Upadhyay AD, Pandey RM, Sinha S, et al. Predictors of Dengue-Related Mortality and Disease Severity in a Tertiary Care Center in North India. *Open Forum Infect Dis* 2017 ;4(2):ofx056.
4. Deshpande D, Srivastava S, Chapagain M, Magombedze G, Martin KR, Cirrincione KN, et al. Ceftazidime-avibactam has potent sterilizing activity against highly drug-resistant tuberculosis. *SciAdv* 2017 30;3(8):e1701102.
5. Sager R, Kutz A, Mueller B, Schuetz P. Procalcitonin-guided diagnosis and antibiotic stewardship revisited. *BMC Med* 2017 ;15(1):15.
6. Vardakas KZ, Voulgaris GL, Maliaros A, Samonis G, Falagas ME. Prolonged versus short-term intravenous infusion of antipseudomonal β -lactams for patients with sepsis: a systematic review and meta-analysis of randomised trials. *Lancet Infect Dis* 2018 ;18(1):108-20.
7. Dorman SE, Schumacher SG, Alland D, Nabeta P, Armstrong DT, King B, et al. Xpert MTB/RIF Ultra for detection of *Mycobacterium tuberculosis* and rifampicin resistance: a prospective multicentre diagnostic accuracy study. *Lancet Infect Dis* 2018;18(1):76-84.
8. Paul M, Daikos GL, Durante-Mangoni E, Yahav D, Carmeli Y, Benattar YD, Skiada A, et al. Colistin alone versus colistin plus meropenem for treatment of severe infections caused by carbapenem-resistant Gram-negative bacteria: an open-label, randomised controlled trial. *Lancet Infect Dis* 2018 ;18(4):391-400.
9. Chotiprasitsakul D, Han JH, Cosgrove SE, Harris AD, Lautenbach E, Conley AT, et al. Comparing the Outcomes of Adults With Enterobacteriaceae Bacteremia Receiving Short-Course Versus Prolonged-Course Antibiotic Therapy in a Multicenter, Propensity Score-Matched Cohort. *Clin Infect Dis* 2018;66(2):172-77.
10. Smit MR, Ochomo EO, Aljayyousi G, Kwambai TK, Abong'o BO, Chen T, et al. Safety and mosquitocidal efficacy of high-dose ivermectin when co-administered with dihydroartemisinin-piperaquine in Kenyan adults with uncomplicated malaria (IVERMAL): a randomised, double-blind, placebo-controlled trial. *Lancet Infect Dis* 2018;18(6):615-26.
11. Hakim JG, Thompson J, Kityo C, Hoppe A, Kambugu A, van Oosterhout JJ, et al. Lopinavir plus nucleoside reverse-transcriptase inhibitors, lopinavir plus raltegravir, or lopinavir monotherapy for second-line treatment of HIV (EARNEST): 144-week follow-up results from a randomised controlled trial. *Lancet Infect Dis* 2018 ;18(1):47-57.

Compiled by:

Dr Deepak Madi

Associate Professor,
Dept. of Medicine
KMC Mangaluru

Section 4

Pictus...
Photo gallery

Manipal Infectious Diseases Conference & MAC ID Annual Day – 22nd & 23rd August, 2017



World Pneumonia Day – 15th November, 2017



Symposium on Optimizing Antibiotic use in Hospitals - 18th November, 2017



World TB Day -19th - 24th March, 2018




World Malaria Day – 25th April 2018



McGill Summer course - Clinical Tropical Medicine
18th - 20th June 2018



From left to right: Drs Chythra. R. Rao, Sapha Barkati, Makeda Semret, Cedric Yansouni, and Michael Libman at this year's Clinical Tropical Medicine course



MAC ID members in the Canadian National Reference Centre for Parasitology. (from left to right) Dr Chythra. R. Rao, Dr. Momar Ndao, and Dr. Shashidhar Vishwanath.



Section 5

Laurus...
MAC ID Faculty achievements

[A]. Awards



Dr. Ramesh Holla

Associate Professor
Department of Community Medicine
Kasturba Medical College, Mangaluru
Manipal Academy of Higher Education (MAHE)

Dr. Ramesh Holla has done M.D. thesis on “A Clinical Evaluation of Safety and Immunogenicity of Purified Chick Embryo Cell Vaccine (PCECV, Rabipur) and Purified Verocell Rabies Vaccine (PVRV, Verorab) Administered as Simulated Post Exposure Prophylaxis using One Week Intradermal Regimen (4-4-4-0-0)” at Anti Rabies Clinic, KIMS, Bangalore.

By considering its safety and efficacy, WHO has recommended this 1 week, four sites regimen as alternative immunogenic intradermal regimens in the recently published WHO Expert Consultation on Rabies, third report. Geneva: World Health Organization; 2018 (WHO Technical Report Series, No. 1012).



He has been awarded Young Scientist Award by the Association for Prevention and Control of Rabies in India (APCRI) at APCRICON 2018, 20th National Conference of Association for Prevention and Control of Rabies in India on 7th and 8th July 2018 at New Delhi from Shri. J P NADDA, Honourable Minister of Health and Family Welfare Govt. of India.

[B]. Publications

(I) MAC ID Affiliated Articles

1. Commons RJ, Simpson JA, Thriemer K, Humphreys GS, Abreha T, Alemu SG, et al. The effect of chloroquine dose and primaquine on Plasmodium vivax recurrence: A World Wide Antimalarial Resistance Network systematic review and individual patient pooled meta-analysis. The Lancet Infectious Diseases. 2018;3099(18):1–10.
2. Hakkimane SS, Shenoy VP, Gaonkar SL, Baiyya I, Guru BR. Antimycobacterial susceptibility evaluation of rifampicin and isoniazid benz-hydrazone in biodegradable polymeric nanoparticles against Mycobacterium tuberculosis H37Rv strain. International Journal of Nanomedicine. 2018;13(July):1–16.

3. Nathavitharana RR, Pai M. New strategies for inpatients with HIV and tuberculosis. *Lancet*. 2018 Jul 28;392(10144):256-258.
4. Pande T, Huddart S, Xavier W, Kulavalli S, Chen T, Pai M, Saravu K. Prevalence of diabetes mellitus amongst hospitalized tuberculosis patients at an Indian tertiary care center: A descriptive analysis. *PLoS ONE* 2018;13(7): e0200838.
5. Pai M. Time for high-burden countries to lead the tuberculosis research agenda. *PLoS Med* 2018;15(3): e1002544.
6. Nash M, Huddart S, Badar S, Baliga S, Saravu K, Pai M. Performance of the Xpert HIV-1 Viral Load Assay: a Systematic Review and Meta-analysis. *J Clin Microbiol* 2018 ;56(4). pii: e01673-17.
7. Huddart S, Nafade V, Pai, M. Tuberculosis: a Persistent Health Challenge for India, *Curr Epidemiol Rep* 2018 ;5:18-23.
8. Weber SF, Saravu K, Heller T, Kadavigere R, Vishwanath S, Gehring S, et al. Point-of-Care Ultrasound for Extrapulmonary Tuberculosis in India: A Prospective Cohort Study in HIV-Positive and HIV-Negative Presumptive Tuberculosis Patients. *Am J Trop Med Hyg*. 2018 ;98(1):266-73.
9. Daftary A, Frick M, Venkatesan N, Pai M. Fighting TB stigma: we need to apply lessons learnt from HIV activism. *BMJ Glob Health* 2017 ;2(4):e000515.
10. Shenoy S, Shrivastava D, Malalur C, Varma M, Kunder S K, Arivazhahan A, et al. Modification of First-line Antiretroviral Therapy in Treatment-naïve, HIV Positive Patients. *J Clin Diagn Res* 2017 ; 11: FC01-FC05.
11. Subbaraju P, Rai S, Morakhia J, Midha G, Kamath A, Saravu K. Clinical - microbiological characterization and risk factors of mortality in infective endocarditis from a tertiary care academic hospital in Southern India. *Indian Heart J* 2018 ;70(2):259-65.
12. Ahlbrand SE, Pai M. A 360-degree view of an ancient killer disease. *J Epidemiol Glob Health*;2017; 7(4): 209-10.
13. Pai M. Do rats pass the sniff test? *Int J Tuberc Lung Dis* 2017 ;21(11):1089-90.
14. Nash M, Ramapuram J, Kaiya R, Huddart S, Pai M, Baliga S. Use of the GeneXpert tuberculosis system for HIV viral load testing in India. *Lancet Glob Health*. 2017;5(8):e754-e755.

(II) Other Articles

1. Holla R, Darshan B, Pandey L, Unnikrishnan B, Kumar N, Thapar R, et al. Leptospirosis in Coastal South India: A Facility Based Study. *Biomed Res Int*. 2018 May 15;2018:1759125.
2. Holla R, Darshan B, Guliani A, Unnikrishnan B, Thapar R, Mithra P, et al. How familiar are our doctors towards Rabies prophylaxis- A study from coastal south India. *PLoS Negl Trop Dis*. 2017 Oct 30;11(10):e0006032.
3. Aithal S, Kumar N, Unnikrishnan B, Thapar R, Mithra P, Kulkarni V, et al. Predictors of anemia among a cohort of people living with HIV on anti-retroviral therapy in a southern state of India. *HIV AIDS Rev* 2018; 17, 2: 122-127.

Crossword solutions (For Crossword on Pg.38)

⁵ M		¹ A	² N	O	P	³ H	E	L	⁴ E	S	⁸ I
E		M	I			⁶ A	P	E	⁷ C	D	M
L		I	P			P			O		M
I	⁹ A	K	A	R	I		¹⁰ D	O	L	O	O
O		A	¹¹ H	A	C	¹² E	K		I		T
I	¹³ J	C				¹⁴ L	A	S	S	¹⁵ A	I
D		¹⁶ I	S	O	N	I	A	Z	I	D	L
O		N	O			S			N	A	E
S			F		¹⁷ M	A	L	A	R	I	¹⁸ A
I			¹⁹ A	M	Y	L	O	I	D		R
S					²⁰ F	E	R	M	E	N	T

Crossword compiled by:
Dr. Tirlangi Praveen Kumar
Senior Resident
Department of Medicine
KMC Manipal

Section 6

Mustus...
Upcoming ID
conference details

National ID conferences

- 1) Name: MYCOCON 2018
Date: 22- 23 September 2018
Venue: Hotel Pride Plaza, Aerocity, New Delhi
URL: <http://www.delhimasterclass.org/index.php>
- 2) Name: APCC 2018
Date: 2-3 November 2018
Venue: Hotel Leela Palace,
Chanakya Puri, New Delhi
URL: <http://www.apcc-india.com/>
- 3) Name: World Congress on Infectious Diseases
And Antibiotics 2018
Date: 28 - 29 November 2018
Venue: J.N. Tata Auditorium, Indian Institute of
Science, Bengaluru Karnataka
URL: <http://www.infectiousdiseasescongress.com/>
- 4) Name: IPHACON 2018
Date: 31 Jan – 3 Feb 2019
Venue: Rangaraya Medical College, Kakinada,
Andhra Pradesh
URL: <http://www.iphacon2019.com/>
- 5) Name: APICON2019
Date: 7 - 10 Feb 2019
Venue: Lulu Bolgatty International Convention
Center, Kochi, Kerala
URL: <http://www.apiconkochi2019.com/>

International ID conferences

- 1) Name: IDWEEK 2018
Date: 3-7 October 2018
Venue: San Francisco, CA
URL: <https://www.idweek.org/>
- 2) Name: 10th Euro-Global Conference on Infectious
Diseases
Date: 27-29 September 2018
Venue: Rome, Italy
URL: <https://infection.conferenceseries.com/europe/>
- 3) Name: National Antimicrobial Resistance and
Stewardship Forum 2018
Date: 1-2 November 2018
Venue: University of Melbourne, Parkville,
Melbourne, Victoria
URL: <https://www.ncas-australia.org/forum2018>
- 4) Name: 7th International Australian College for
Infection Prevention and Control Annual Conference
Date: 19 – 21 November 2018
Venue: Brisbane Convention and Exhibition Center,
Brisbane QLD, Australia
URL: <http://www.acipconference.com.au/>
- 5) Name: 12th Edition of International Conference on
Infectious Diseases
Date: 22 -23 April 2019
Venue: Rome, Italy
URL: <https://infectious-diseases.euroscicon.com/>
- 6) Name: ECCMID 2019
Date: 13 - 16 April 2019
Venue: GZ Amsterdam, Netherlands
URL: http://www.eccmid.org/eccmid_2019/

Section 7

Numus...
Our Sponsors

Sponsors

We acknowledge the support extended by our sponsors:

Indian Council of Medical Research (ICMR)		Manipal Health Enterprises Pvt Ltd (MHEPL)	
Cipla	Hetero (HIV division)	Pfizer (Critical Care and Vaccine)	Bio Merieux India Pvt Ltd
Ortho Clinical Diagnostics, India	Cepheid India Pvt Ltd	Biocon (Critical care)	la Renon (Critical care)
Macleods	Mylan (HIV)	GSK	Lividus
TMS Tulsi	Glenmark	Akesis	BD India Pvt Ltd
CPC Diagnostics Pvt Ltd	Aroteza Life Science	British Biologicals	Maruthi Suzuki Nexa
Karnataka Bank	Emcure	Lupin	Strive

A complete profiling solution

PlexMAT4
A MULTITASKER IN PROFILING




KEY FEATURES

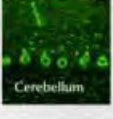



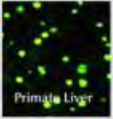
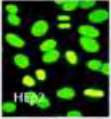
Easy handling
Minimum of one test per run
Reagent Saving Available
Automatic reading of probe
Up to 4 strips per run
More than 10 Predefined assays in different groups
Predefined with EUROline Scan software



EUROIMMUN



Indirect Immunofluorescence:
Gold standard for the serological diagnosis of autoimmune diseases



Advantages of Euroimmun's IIFT

1. Combination of different substrates in one test field using Biochip Mosaics
2. High specificity through visual discrimination of patterns
3. One substrate screening of 100 different antibodies with Htp2010 - differentiation and confirmation using Primate Liver
4. 100% Specificity and 100% Sensitivity using transfected cells

Tests available

1. ANA Testing
2. ANCA Testing
3. Autoimmune Neuronal Disease Diagnosis
4. Autoimmune Liver Disease Diagnosis
5. Celiac Disease Diagnosis
6. Inflammatory Bowel Disease Diagnosis

Opportunities for MAC ID Members

- Opportunity to apply for seed grants from MAC ID
- Student fellowships: funding for students who work on projects and/or to attend national conferences and workshops
- Mentoring opportunity: to receive highly qualified trainees from McGill, or to send Manipal Academy of Higher Education trainees to McGill for specific skills/training
- Opportunity to participate in McGill Summer Institute courses
- Collaborate on MAC ID research projects and international grant proposals (e.g. CIHR, Gates, NIH)
- To learn about potential grant opportunities in the area of ID
- Members and their ID research will be showcased on the MAC ID website
- Conducting/ supporting infectious disease conference/training in Manipal/Mangaluru campuses
- Conducting MAC ID annual research day



Publication by

**Manipal McGill Centre for
Infectious Diseases (MAC ID)**

Prasanna School of Public Health

Manipal Academy of Higher Education, Manipal